

**PLANT HISTOLOGY**

Plant tissues are divided into two groups:

- (a) **Simple plant tissues** consisting of one type of cell, which are **parenchyma**, **collenchyma**, and **sclerenchyma**.
- (b) **Complex plant tissues** consisting of more than one type of cell, which are **xylem** and **phloem**.

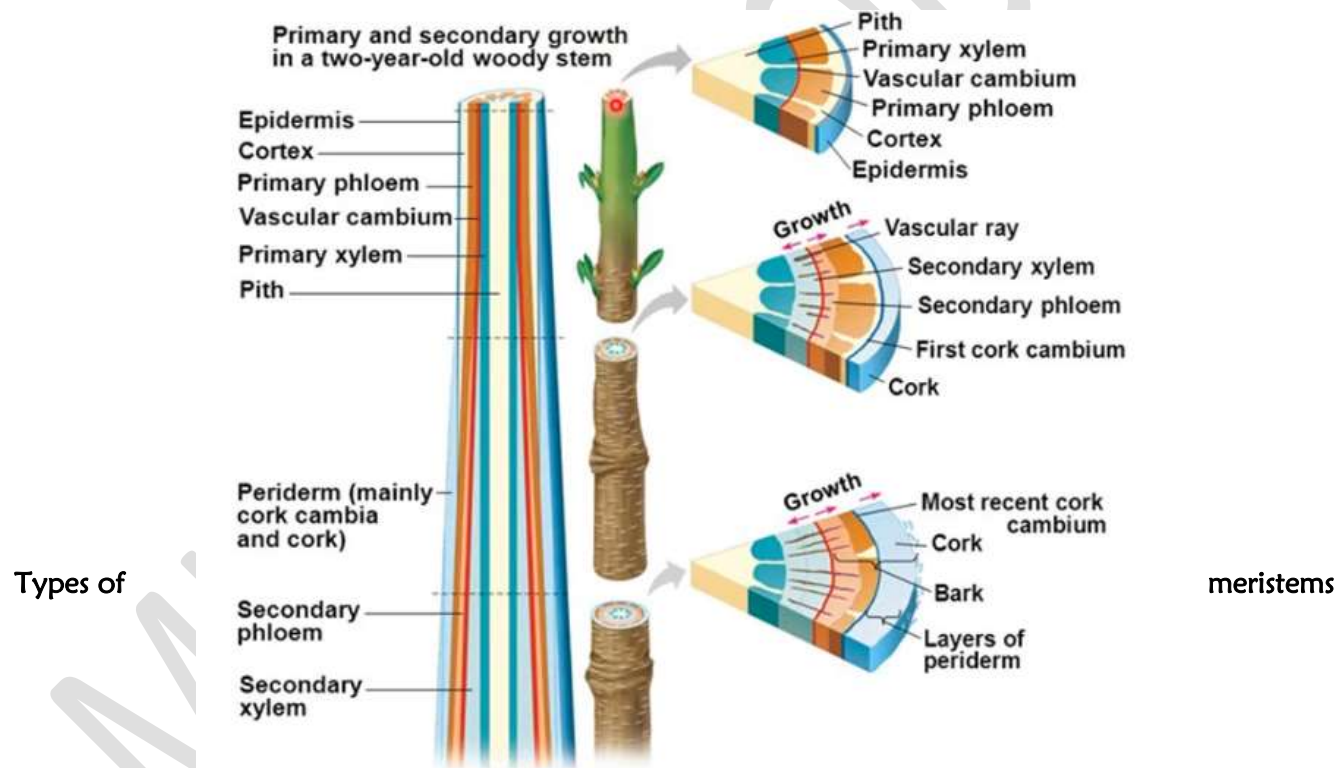
**1. MERISTEMATIC TISSUE**

**Meristematic tissue** is plant tissue consisting of actively dividing cells that give rise to cells which differentiate into new tissues of the plant.

A **meristem** is a group of cells which retain the ability to divide by mitosis producing daughter cells, which grow to form the rest of the plant body.

**The structure of meristematic tissue**

- Comprises small cuboidal cells
- Cells have thin cellulose cell walls
- Cells have few, small vacuoles
- Cells possess undifferentiated plastids called **proplastids**
- Cells are tightly packed together, with no obvious air spaces between them



Types of

meristems

TYPE OF MERISTEM	DISTRIBUTION	ROLE AND FUNCTION
1. Apical meristems	Root and shoot tips	<ul style="list-style-type: none"> <li>• Divide continuously by mitosis, leading to primary growth of the plant body</li> <li>• Causes increase in length of shoot or root</li> </ul>
2. Lateral meristems (cambium)	Laterally located in older parts of the plant, parallel with the long axis of	<ul style="list-style-type: none"> <li>• Cause secondary growth of roots and shoots</li> <li>• <b>Vascular cambium</b> gives rise to secondary vascular tissue, including secondary phloem and secondary xylem (<b>wood</b>)</li> </ul>

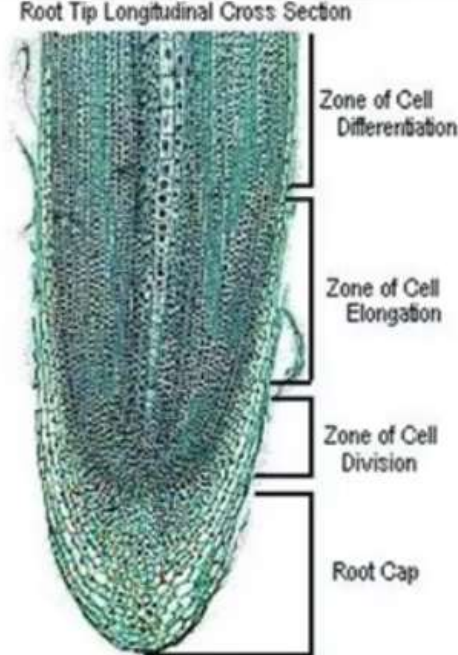
TYPE OF MERISTEM	DISTRIBUTION	ROLE AND FUNCTION
	plant organs, for example <b>cork cambium</b> (phellogen), <b>vascular cambium</b>	<ul style="list-style-type: none"> <li>• <b>Cork cambium</b> gives rise to <b>periderm</b>, which replaces the epidermis, and includes <b>cork</b></li> <li>• Lateral meristems cause increase in girth</li> </ul>
<b>3. Intercalary meristems</b>	Located between regions of permanent tissues, such as at nodes of monocots, for example at leaf bases of grasses	<ul style="list-style-type: none"> <li>• Causes growth in length in regions other than the root and shoot tips</li> <li>• Causes increase in length of the plant body</li> <li>• Ensures continued growth where tissues are damaged, such as when eaten by herbivores in grasses and wave action in kelps (tidal monocots)</li> </ul>

## Primary Growth

---

Another important structure of a plant is the **root cap**.

- The structure covers the apical meristem
- Made of very tough tissue to push through the ground



Root Tip Longitudinal Cross Section

Zone of Cell Differentiation

Zone of Cell Elongation

Zone of Cell Division

Root Cap

A) SIMPLE PLANT TISSUES 1.

## PARENCHYMA

### The structure of parenchyma tissue

- Comprises relatively undifferentiated living cells
- Cell walls comprise cellulose, pectins, and hemicelluloses
- Cells are either roughly spherical or elongated
- Cells have thin cell walls
- Cells have air spaces between them
- Cells have large central vacuoles, and thin peripheral cytoplasm

### Distribution of parenchyma

- Located in the cortex, pith and medullary rays in wood
- As packing tissue in xylem and phloem

### Functions of parenchyma

- Functions as packing tissue between more specialized tissue of the plant, as in the cortex
- Parenchyma is metabolically active as it is composed of living cells, for example, some parenchyma is

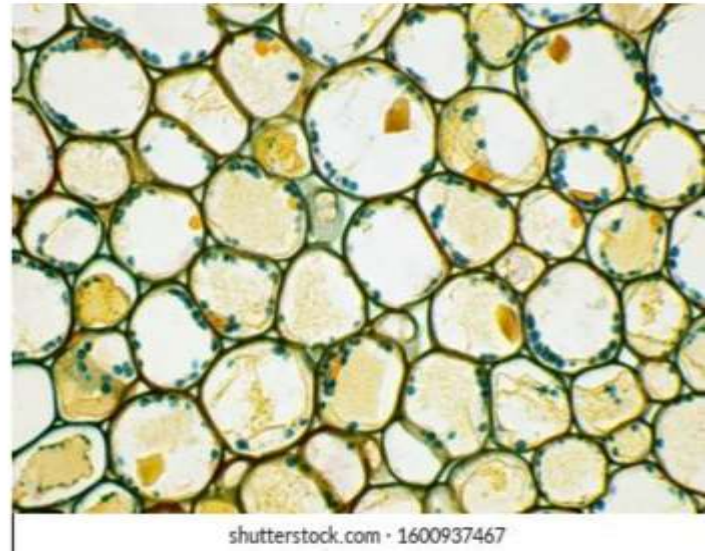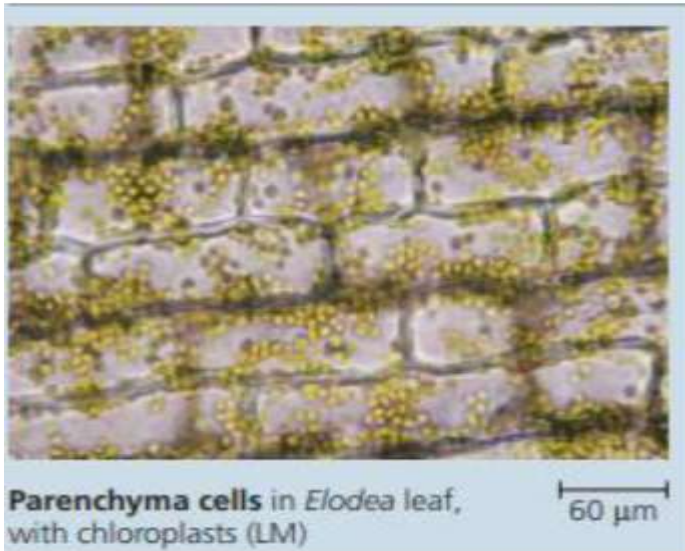
photosynthetic

- Contains intercellular air spaces which allow gaseous exchange
- Storage of food due to possession of starch granules and large food vacuoles
- Transport of materials through cells or cell walls
- Turgid parenchyma cells provide support to herbaceous plants and non-woody parts of the woody plants

An illustration of the structure of parenchyma BS 169 (a)

10 lines

## Parenchyma



### Adaptations of parenchyma to its function

- Unspecialized cells to perform a variety of functions.
- Many intercellular spaces permit rapid diffusion of gases during gaseous exchange.
- Isodiametric, roughly spherical or elongated cells to serve as packing material between specialized cells.
- Thin cellulose cell walls to permit rapid passage of materials.
- Transparent cell walls permit entry of light for photosynthesis.
- Permeable cell walls permit entry of water which causes turgidity.
- Large cells with large vacuoles to provide space for storage of materials.
- Cells have chloroplasts for photosynthesis.
- Cells have leucoplasts such as amyloplasts to store food such as starch.
- Cells contain large quantities of sap to provide support by turgidity
- Cell walls contain cellulose, pectins, and hemicelluloses for support

### MODIFIED PARENCHYMA

Modified parenchyma includes; epidermis, mesophyll, endodermis, pericycle, companion cells and transfer cells.

(a) Epidermis/epidermal cells

### The structure of epidermis

- Comprises living, elongated and flattened cells.
- The cell wall comprises of cellulose, pectins and hemicelluloses, and a covering of cutin.

**Distribution of the epidermis:** Occurs as a single layer of cells covering the entire plant body.

### Functions of epidermis

- Protection of the plant body from desiccation and infection.
- Hairs and glands serve additional functions.

### A transverse section through the epidermis BS 171(a)

7 lines

### Modifications of the parenchyma to perform its functions as epidermis

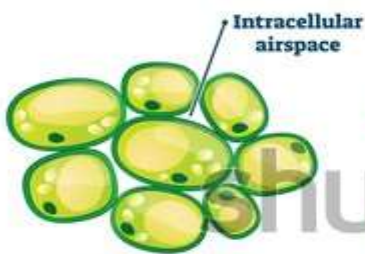
- Transparent, to allow passage of light to the mesophyll cells for photosynthesis.
- Thick and tough to protect the inner tissues from mechanical damage.
- The epidermis secretes a waxy cuticle to reduce water loss and prevent pathogen entry.
- Some epidermal cells are modified into guard cells which control the opening and closing of stomata pores.
- In roots, the epidermal cells grow unicellular, hair-like extensions, called root hairs which increase surface area for absorption of water and mineral salts.
- In climbing plants, the epidermal cells develop hooked hairs to prevent the stems slipping from their support as in goose grass.
- The epidermal hairs of leaves and stems (pubescence) reduce water loss from the plant tissue, by trapping a film of moist air near the plant, as well as reflecting the Sun's radiation.

## TYPES OF PLANT TISSUE

### Parenchyma tissue

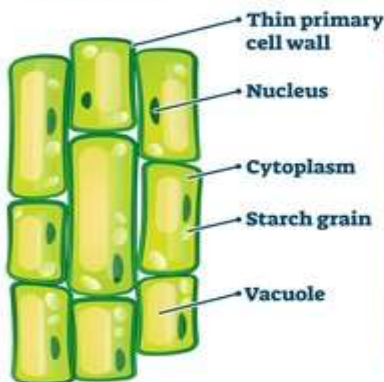


Potato



Intracellular  
airspace

Cross section



Longitudinal

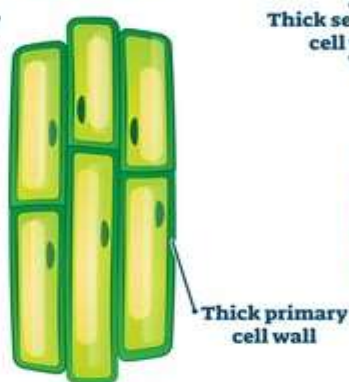
### Collenchyma tissue



Celery



Cross section

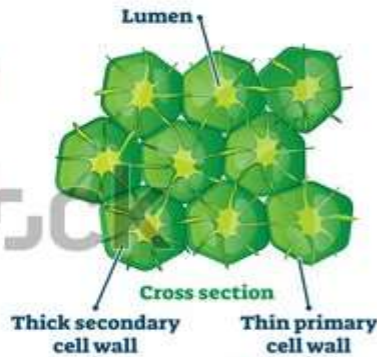


Longitudinal

### Sclerenchyma tissue

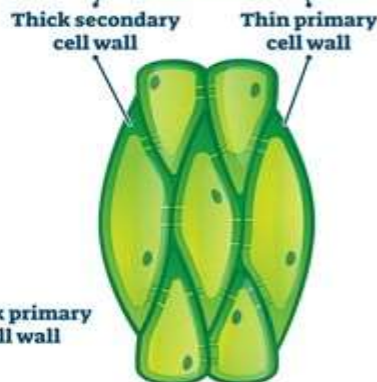


Pear



Lumen

Cross section



Longitudinal

- Some epidermal hairs are short and stiff to offer mechanical support and discourage herbivores, as in the stinging nettle.
- The epidermis may develop hairs which form a barrier around the nectaries of flowers preventing access to crawling insects and promote cross pollination by large flying insects.
- Some epidermal cells are glandular and may secrete a sticky substance that traps and kills insects, either for protection, or if the secretion contain enzymes, for digestion and subsequent absorption of food nutrients as in insectivorous plants such as the pitcher plant.
- Some epithelial cells develop glandular hairs which produce scent needed to attract agents of pollination and dispersal, as in lavender.
- In some plants, the epidermis contains chloroplasts with chlorophyll for photosynthesis.

**Note:** During secondary growth the epidermis may be ruptured and replaced by a cork layer.

(b) **Mesophyll cells (chlorenchyma)**

**Mesophyll** is **packing tissue** located between the upper and lower epidermis of leaves, consisting of parenchyma modified for photosynthesis.

Photosynthetic parenchyma is called **chlorenchyma**.

The cytoplasm of mesophyll cells contains chloroplasts which contain chlorophyll for photosynthesis.

**An illustration of the mesophyll cells BS 200 (7.5)**

12 lines

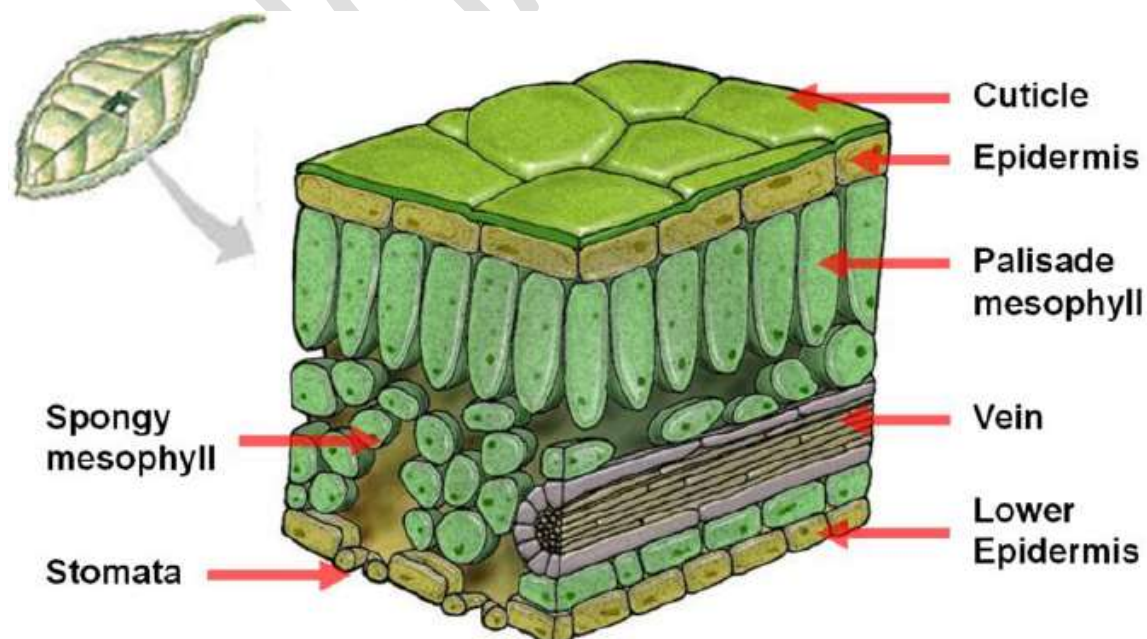
There are **two types of mesophyll cells**:

(i) **Palisade mesophyll cells**

- Located in the upper layer called the palisade mesophyll.
- Cells are elongated and column-shaped.
- Contain a large number of chloroplasts.
- Cells are tightly packed together with very few and narrow air spaces.

(ii) **Spongy mesophyll cells**

- Located in the lower layer called the spongy mesophyll.
- Cells are spherical and irregularly shaped
- Contain fewer chloroplasts.
- Possess large intercellular air spaces between the cells.



**00Distribution of mesophyll cells:** Located between the upper and lower epidermis of leaves

### Functions of mesophyll

- Photosynthesis
- Gaseous exchange
- Storage of starch

### How parenchyma is modified to perform its functions as mesophyll

- Palisade mesophyll cells contain numerous chloroplasts with much chlorophyll for photosynthesis.
- Palisade mesophyll cells are column-shaped and tightly packed together forming a continuous layer that absorbs in-coming light.
- The chloroplasts within the mesophyll cells can move towards light allowing them to arrange themselves in the best positions to receive light.
- Chlorophyll within chloroplasts is contained within the grana, where it is arranged on the sides of a series of unit membrane allowing chlorophyll to receive maximum light.
- The structured arrangement of chlorophyll on the photosynthetic membrane brings chlorophyll in close proximity to other pigments and substances, such as carotenoids and enzymes necessary for its functioning during light-harvesting.
- Spongy mesophyll cells are irregularly shaped, hence fit together loosely, leaving large air spaces to allow efficient gaseous exchange via the stomata.
- Mesophyll cells contain numerous amyloplasts for storing starch.

### (c) Endodermis

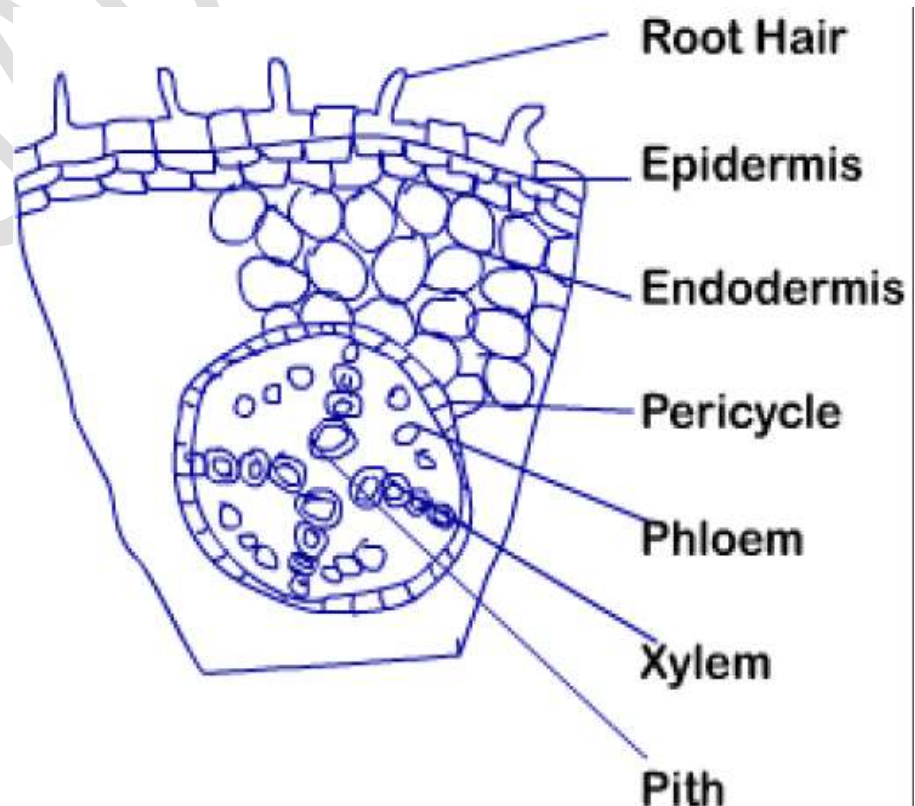
The **endodermis** is the innermost layer of the cortex, surrounding the vascular tissue of roots and stems.

#### The structure of the endodermis

- Consists of living, elongated and flattened cells.
- The cell walls of endodermal cells comprise cellulose, pectins, hemicelluloses, and in places deposits of suberin.

**A transverse section of a root showing the epidermis, cortex, endodermis and pericycle BS 448(a)**

12 lines



The distribution of the endodermis

Found in the innermost layer of the cortex, surrounding the vascular tissue of roots and stems.

### Functions of the endodermis

- Functions as a selective barrier to movement of water and mineral salts between the cortex and xylem in roots.
- In dicot stems, the endodermis stores starch forming a **starch sheath**, with a possible role in the gravity response of stems.

### How parenchyma is modified to perform its functions as endodermis

- Each endodermal cell develops a Casparian strip, a band of suberin that runs round the cell, which is impermeable to water, and prevents water and solutes from flowing through the spaces of the cell walls of the endodermal cells, forcing water and solutes to pass through the cell surface membrane and into the cytoplasm of endodermal cells.
- The Casparian strip of endodermal cells controls and regulates the movement of solutes and water through the xylem, a protective measure against the entry of pathogens and toxic substances into the xylem.
- In dicot stems, endodermal cells contain amyloplasts for storing starch grains forming a starch sheath, whose response to gravity enables plant geotropic response.

### (d) Pericycle

The **pericycle** is a layer of modified parenchyma, one to several cells thick, located in roots between the central vascular tissue and the endodermis.

### The structure of the pericycle

- Consists of one to several layers of living, roughly spherical and elongated cells.
- Cells of the pericycle have cell walls composed of cellulose, pectins and hemicelluloses.

### The distribution of the pericycle

Located in roots between the central vascular tissue and the endodermis.

### Functions of the pericycle

- Produces lateral roots.
- Contributes to secondary growth.

### Modifications of the parenchyma to perform its functions as pericycle

- Retains its capacity for cell division (meristematic activity) to produce lateral roots.
- Due to its meristematic activity, the pericycle contributes to secondary thickening of the root.

### (e) Companion cells

**Companion cells** are specialized parenchyma cells found adjacent to sieve tubes

### The distribution of companion cells

Adjacent to sieve tubes of the phloem

### The structure of companion cells

- Have a prominent nucleus, dense cytoplasm with numerous small vacuoles, plastids and the usual cell organelles.
- Are metabolically very active, with numerous mitochondria and ribosomes.
- Each companion cell is connected to a sieve element by plasmodesmata.

**A longitudinal section through the phloem showing the relationship between a sieve tube element and a companion cell TT 469**

**20 lines**

### Functions of companion cells

- Control the activity of the adjacent metabolically-inactive sieve tube elements.
- Provide energy needed for active processes which occur during translocation of organic solutes in the sieve tubes.

### Modifications of the parenchyma to perform its functions as companion cells

- Plasmodesmata connect sieve elements with companion cells, allowing communication and exchange of materials between companion cells and sieve tube elements.
- Companion cells have a large nucleus to effect metabolic control over both the companion cells and sieve tube elements.
- Companion cells contain numerous mitochondria, to produce energy for active transport of materials in the sieve tube elements.

### (f) Transfer cells

Transfer cells are a modified form of parenchymatous companion cell found next to the sieve tube elements of the phloem.

#### The structure of transfer cells

- Transfer cells have numerous internal projections of the cell wall formed by extra thickening of the cell wall.
- Possess numerous mitochondria in the dense cytoplasm.

#### Function of transfer cells

- Active uptake of salts from neighboring cells

#### Distribution of transfer cells

- Found adjacent to sieve tubes of phloem

### Modifications of parenchyma to perform its functions as transfer cells

- Numerous internal projections of the cell wall, increase the surface area of the cell surface membrane, lining the cell wall, and bring into closer association with the cytoplasm.
- Numerous mitochondria in the cytoplasm provide energy for active transport of organic solutes such as sugars from neighboring cells.

## 3. COLLENCHYMA

Collenchyma consists of living cells modified to give support and mechanical strength.

The collenchyma is the first mechanical tissue to develop in the primary plant body.

#### The structure of collenchyma

- Consists of living cells.
- Cell walls consist of cellulose, pectins and hemicelluloses.
- Cells are closely packed, with thick cell walls.
- Cells are elongated and polygonal, with tapering ends.
- Extra deposition of cellulose at the corners of the cells causing **uneven thickening** of cell walls.
- Cells elongated parallel to the longitudinal axis, of the organ in which they are found.

#### Distribution of collenchyma

- Outer region of the cortex, as at angles of the stem and midribs of leaves.
- Collenchyma is the first strengthening tissue to develop in the primary plant body.
- Important in young plants, herbaceous plants, and in organs such as leaves, and flowers where secondary growth does not occur.

#### Functions of collenchyma

- Collenchyma is mechanical strengthening tissue.
- Provides support for those organs where it is found

**An illustration of the transverse section of collenchyma cells BS 173(a)**

**10 lines**

**An illustration of the longitudinal section of collenchyma cells BS 173(b)**

**10 lines**

**Adaptations of collenchyma to its function**

- Deposition of extra cellulose at the corner of cells leads to development of unevenly thickened cell walls to provide mechanical support.
- Cells are polygonal, closely packed and elongated parallel to the longitudinal axis of the organ where they are found to provide support and mechanical strength.
- Cells are living and can grow and stretch, thus provide mechanical strength without imposing limitations on the growth of other cells around it, allowing continued growth in young stems and leaves.
- Located towards the periphery of the organ just below the epidermis in the outer regions of the cortex to increase its support value in stems and petioles
- Collenchyma is distributed in young herbaceous plants and organs without secondary growth in order to supplement the support provided by turgid parenchyma.

#### 4. SCLERENCHYMA

**Sclerenchyma** is mechanical tissue which provides support and mechanical strength of the plant. The distribution of sclerenchyma is related to the stresses to which different organs are subjected.

##### The structure of sclerenchyma

- Mature cells are dead.
- Mature cells contain no cytoplasm.
- The primary cell wall is heavily thickened with deposits of lignin.
- Its thick cell walls contain **simple pits** - areas where lignin is not deposited on the primary cell wall due to presence of groups of plasmodesmata.
- There are **two types of sclerenchyma cells: Fibres and sclereids (stone cells)**

##### (a) Fibres

###### Structure of fibres

- Dead cells with no cytoplasm.
- Thick cell walls composed of lignin, cellulose, pectins and hemicelluloses.
- Cells are elongated and hollow, with narrow lumina /lumens
- Cells are polygonal in shape, with tapering, interlocking ends.

##### (b) Sclereids (stone cells)

###### Structure of sclereids

- Dead cells with no cytoplasm.
- Thick cell walls composed of lignin, cellulose, pectins and hemicelluloses.
- Cells have rough spherical or irregularly-shaped.

##### Distribution of sclerenchyma

**Distribution of fibre cells:** Outer regions of the cortex, pericycle of stems, xylem and phloem of stems, phloem of stems, leaves and roots.

**Distribution of sclereids (stone cells):** Located in the cortex, pith, phloem, shells and stones of fruits, seed coats.

##### An illustration of the transverse section of sclerenchyma cells BS 175(a)

9 lines

##### Illustrations of the longitudinal section and 3-dimensional structures of sclerenchyma cells

##### (b) Longitudinal section BS 175(b)

(b)3-dimensional structures BS 175(c)

8 lines

##### The structure of sclerenchyma sclereids BS 176(a)

8 lines

##### An illustration of the process of development of simple pits in sclerenchyma fibres and sclereids BS 176 (Fig 6.8)

8 lines

##### Functions of sclerenchyma

- Fibres are for support, while sclereids are for support and mechanical protection.

- Hollow structures permit easy flow of materials.
- Narrow lumens of fibres cause capillarity.

#### **Adaptations of sclerenchyma to its function**

- Elongated fibres and spherical sclereids closely packed together to provide mechanical support.
- Primary cell walls heavily thickened and lignified with heavy deposits of lignin, with great tensile and compression strength for support and mechanical protection.
- High tensile strength of lignified walls prevents breakage on stretching.
- High compression strength of lignified walls prevents buckling or crushing under pressure.
- Fibres are arranged into strands or sheets of tissue that extend longitudinally to provide combined collective strength.
- Ends of cells of fibres, interlock with the tapering ends of one another increasing combined supportive strength.

### **B) COMPLEX PLANT TISSUES**

#### **5. XYLEM**

**Xylem** is vascular tissue with two main functions; the **conduction of water and mineral salts**, and providing **mechanical support** to the plant.

##### **The structure of xylem**

Xylem consists of **four types of cells; tracheids, vessel elements, parenchyma and fibres.**

##### **(a) Xylem tracheids**

- Tracheids are single cells with thick walls, extensively lignified by heavy deposits of lignin.
- Have tapering end walls that overlap with adjacent tracheids.
- Tracheids are dead, with no cytoplasm, empty lumens when mature.
- End walls of tracheids are perforated by **bordered pits**.

##### **(b) Xylem vessels**

- **Xylem vessels** are very long, tubular structures, formed by fusion of several elongated cylindrical cells end-to-end in a row.
- Each cell of a xylem vessel is called a **vessel element**.
- Vessel elements are shorter and wider than tracheids.
- A vessel is formed when neighboring vessel elements of a given row fuse as a result of their end walls breaking down.
- A series of rims is left around the inner side of the vessel, marking the remains of the end walls.

##### **Protoxylem and metaxylem**

**Protoxylems** are the first formed xylem vessels, found in the expanding region of roots and shoots at the apex, just behind the apical meristem; before the shoot or root has completed the process of elongation.

Mature protoxylem vessels can be stretched as surrounding cells elongate, because lignin is not deposited over the entire cellulose wall, but only in rings or spirals.

Protoxylem soon dies, and gets crushed and stretched to the point of collapsing as growth continues around; leading to development of **metaxylem** which replaces the protoxylem.

**Metaxylem** is part of the primary xylem that develops in the plant after the stem or root has completed elongation.

Walls of the metaxylem are more extensively lignified than those of the protoxylem.

Metaxylem vessels show three basic patterns of lignification; **scalariform, reticulate** and **pitted**.

Mature metaxylem vessels cannot stretch or grow because they are dead, rigid and fully lignified tubules.

Metaxylem becomes part of the permanent tissues of the plant.

##### **(c) Xylem parenchyma**

Xylem parenchyma occurs in both secondary and primary xylem, but it is more extensive in secondary xylem. Two systems of parenchyma exist in secondary xylem, derived from meristematic cells called **ray initials** and **fusiform initials**.

Ray parenchyma is more extensive than fusiform parenchyma.

**Ray parenchyma** forms radial sheets of tissue called **medullary rays** which maintain a living link through the wood between the pith and cortex.

Fusiform initials normally give rise to xylem vessels or phloem sieve tubes and companion cells; but occasionally they give rise to parenchyma cells.

**Fusiform parenchyma** cells form vertical rows of parenchyma in the secondary xylem.

#### (d) Xylem fibres

Xylem fibres are shorter and narrower than tracheids, and have much thicker walls.

Xylem fibres have pits similar to those in tracheids.

Xylem fibres closely resemble sclerenchyma fibres, and have overlapping end walls.

Xylem fibres do not conduct water; have much thicker walls and narrower lumens than the xylem vessels; hence provide additional mechanical strength to the xylem.

#### A transverse section of primary xylem BS 177(a)

11 lines

#### A longitudinal section and 3-dimensional structure of primary xylem BS 177(b)

##### (a) Longitudinal section

13 lines

##### (b) 3-dimensional structure

#### An illustration of the fusion of vessel elements to form a vessel BS 178(Fig 6.11)

6 lines

#### The structure of the protoxylem showing annular thickening and spiral thickening BS 179

9 lines

#### The structure of metaxylem showing a pitted vessel and reticulate thickening BS 180

10 lines

**Note:** Scalariform thickening is similar to reticular but with fewer interconnections between the bars of thickening; and usually grades into reticulate thickening by progressive lignification.

#### The 3-dimensional structure of a tracheid BS 178(a)

7 lines

#### A transverse section of a bordered pit BS 180(g)

7 lines

**Distribution of xylem:** Located in the vascular system of the plant over the whole plant body in roots, stems, leaves and flowers.

#### Functions of xylem

- Tracheids and vessels conduct water and mineral salts.
- Provides mechanical support to the plant.
- Xylem parenchyma has functions which include; Food storage, Deposition of tannins, crystals and so on, Radial transport of food and water, Gaseous exchange through the intercellular spaces

#### Adaptations of xylem to its functions

- Xylem vessels and tracheids consist of long cylindrical cells joined end-to-end, thus are continuous with each other ensuring continuous flow of water in an unbroken column.
- End walls of xylem vessels are completely broken down to form continuous tubes that allow uninterrupted flow of water.
- Tracheids have tapering, elongated, sloping end walls that overlap with adjacent tracheids, perforated with large cellulose-lined bordered pits, that allow water to pass from one cell to another
- During development, the protoplasmic contents of vessels and tracheids die leaving empty hollow lumens,

permitting uninterrupted flow of water without obstruction by living contents.

- Side walls of vessels and tracheids are perforated with numerous pits permitting lateral flow of water and salts in and out of the lumen where necessary.
- Cell walls of tracheids and vessels are impregnated with lignin making the walls impermeable to water and salts, preventing leakage of contents during transport.
- Lignification of walls confers rigidity, preventing walls collapsing under the large tension forces set up by the transpiration pull.
- Impregnation of cellulose walls with lignin increases adhesion of water molecules to the walls, thereby facilitating the rise of water by capillarity.
- Narrowness of lumens of vessels and tracheids increases the rise of water by capillarity.
- Extreme narrowness of lumens of tracheids and vessels offers them high tensile strength, preventing xylem collapsing during transport of water through them.
- Xylem fibres have extremely thick walls which are heavily lignified and narrow lumens, to provide additional mechanical strength and support to the xylem.
- Vessel, tracheids and fibres are dead at maturity, and thus provide mechanical strength and support to the plant.
- Xylem parenchyma maintains a living link through wood between the pith and the cortex; allowing food storage, deposition of tannins and crystals, radial transport of food and water, and gaseous exchange through the intercellular spaces.
- Xylem is centrally located in the vascular system of roots, to withstand strains as the aerial part of the plant bend and lean over.
- Xylem occurs peripherally in a ring in dicotyledonous stems, and scattered in monocotyledonous stems such that separate rods run through the structure to provide more support.
- Secondary xylem is added by secondary growth to support the enlarged structure of trees and shrubs as they undergo secondary growth and increase in girth.
- The nature and extent of thickness of xylem is modified by the extent of the stresses received by the growing plant, so that reinforcement growth can occur and provide maximum support

## 6. PHLOEM

**Phloem** is vascular tissue modified for translocation of organic solutes.

### The structure of phloem

**Phloem** is composed of **five types of cell**; **sieve tube elements, companion cells, parenchyma, fibres and sclereids.**

#### (a) Sieve tubes and companion cells

**Sieve tubes** are long tube-like structures, formed by end-to-end fusion of cells called **sieve tube elements/sieve elements.**

Rows of sieve elements develop from procambial strands of the apical meristems where primary phloem develops, together with primary xylem in vascular bundles.

#### Protophloem and metaphloem

**Protophloem** is the first phloem formed in the zone of elongation of the growing root or stem.

Protophloem becomes stretched and eventually collapses, becoming non-functional, as the tissue around it grows.

As more phloem is produced, the protophloem matures after elongation has stopped, to produce **metaphloem.**

#### Sieve tube elements

Sieve tube elements have walls made of cellulose and pectins, but their nuclei degenerate, and are lost as they mature.

The cytoplasm is confined to a thin layer around the periphery of the cell.

Sieve elements are living, but metabolically dependent on adjacent companion cells.

In between sieve tube elements are **sieve plates**, formed from the two adjoining end walls of neighboring sieve elements.

Sieve plates are perforated by **sieve pores**, formed by enlargement of plasmodesmata.

Sieve plates mark successive sieve elements.

Secondary phloem develops from vascular cambium and is crossed by bands of lignified fibres and medullary rays of parenchyma.

### **Companion cells**

Companion cells have a thin cell wall, and dense cytoplasm, with a prominent large nucleus, numerous mitochondria, plastids, and small vacuoles, and extensive endoplasmic reticulum.

Companion cells are metabolically active, and essential for the survival of sieve elements.

### **(b) Phloem parenchyma, fibre and sclereids**

Phloem parenchyma and fibres are found in dicots, but not in monocots.

Phloem parenchyma is composed of elongated cells.

In secondary phloem, parenchyma occurs in medullary rays and vertical strands.

Phloem fibres are exactly similar to sclerenchyma, and commonly found in secondary phloem in dicots than in primary phloem.

Sclereids occur mostly in older phloem.

**Distribution of phloem:** Located in the in the vascular system of a plant, in leaves, roots, stems and flowers.

### **Adaptations of the phloem for its function**

- Sieve tube elements are joined end to end; their walls are perforated with sieve pores in sieve plates, allowing passage of materials unimpeded from one cell to another.
- Sieve elements lack nuclei, and possess a thin cytoplasm pushed to the sides of the cell, creating room for passage of organic materials in solution with minimal obstruction.
- Plasmodesmata connect sieve elements to companion cells which are metabolically active, allowing communication and exchange of materials between sieve elements and companion cells.
- Sieve elements contain fine cytoplasmic filaments, continuous with similar filaments in other sieve elements via sieve pores in the sieve plate; which consist of a contractile phloem protein capable of streaming and sliding organic materials from one sieve element to another by wave-like movements of the filaments.
- Companion cells contain dense cytoplasm with numerous mitochondria, a large nucleus, plastids, small vacuoles and extensive endoplasmic reticulum; making them metabolically active to meet the metabolic needs of sieve elements.
- Companion cells possess numerous mitochondria to provide energy in form of ATP for the active transport of materials.
- Modified parenchymatous companion cells called transfer cells found next to sieve tubes bear numerous internal projections increasing the surface area of the cell membrane, and
- Numerous mitochondria in transfer cells provide energy for active uptake of solutes from neighboring cells during loading of sieve tubes.
- Phloem consists of living cells allowing live active transport of materials, since the mechanism of loading sieve tubes and transport of solutes requires energy.
- Sclereids are lignified to provide support to the vascular tissue of the phloem.
- Companion cells have a prominent large nucleus to effect control over both the companion cell and sieve tube element.

### **An explanation of the distribution of mechanical tissues of plants**

#### **Collenchyma:**

- Collenchyma is distributed in young herbaceous plants and organs without secondary growth in order to supplement the support provided by turgid parenchyma.

- Closely packed cells, elongated parallel to the longitudinal axis of the organ in which they are found to provide support and mechanical strength
- Collenchyma is distributed in stems and petioles at the periphery just below the epidermis in the outer region of the cortex, to increase its value as supportive tissue.
- Forms 3-dimensional hollow cylinders in stems and petioles, strengthening ridges along fleshy petioles and angular stems, or solid masses running the length of the midrib in dicotyledonous leaves to support vascular bundles.

#### **Sclerenchyma:**

- Sclerenchyma is distributed peripherally according to the degree of stress to which the organs are subjected, to provide support.
- Arranged into strands or sheets of tissue that extend longitudinally to provide combined collective strength and firmness.
- Sclerenchyma fibres are located in the outer regions of the cortex, pericycle of stems, xylem and phloem of stems, leaves and roots, to provide support
- Sclereids occur in the cortex, pith, phloem, shells and stones of fruits, and seed coats, to provide support and mechanical protection

#### **Xylem:**

- Xylem is centrally located in the vascular system of roots, to withstand strains as aerial parts of the plant bend and lean over.
- Xylem is peripheral in a ring in dicotyledonous stems and scattered in monocotyledonous stems such that separate rods run through the structure, to provide more support.
- Secondary xylem is added on primary xylem by secondary growth to support the large structure of trees and shrubs as they undergo secondary growth and increase in girth.
- The nature and extent of thickness of xylem is modified by the extent of the stresses received by the growing plant, so that reinforcement growth can occur and provide maximum support

#### **Structural differences between collenchyma and sclerenchyma**

<b>COLLENCYMA</b>	<b>SCLERENCHYMA</b>
1. Walls not lignified	1. Walls are lignified
2. Unevenly thickened walls	2. Evenly thickened walls
3. Protoplasm present at maturity	3. Protoplasm not present at maturity
4. No pits are present in the cell wall	4. Simple pits are present in the cell wall

### **ANIMAL HISTOLOGY**

Animal tissues are divided into four groups:

- Connective tissue** which includes **fibrous tissue, bone and cartilage, adipose tissue, and blood.**
- Epithelial tissue**
- Muscle tissue**
- Nervous tissue**

#### **(A) EPITHELIAL TISSUE**

**Epithelial tissue** consists of single or multi-layered sheets of closely packed cells, specialized to form the covering or lining of all internal and external body surfaces of animals.

Epithelial tissue that lines the inner surface of the body is called **endothelium**, as in the inside of the heart, blood vessels and lymph vessels.

Epithelial tissue that covers the outer surface of the body is called **epithelium**, such as the skin.

### Characteristics of epithelial tissue

#### (i) Cellularity:

- Epithelial tissue consists of tightly packed cells that are firmly attached to each other with little intercellular material between them.
- Epithelial cells are firmly held together by small amounts of a carbohydrate-based cementing substance, and by special intercellular junctions between the cells; which may be **anchoring junctions** or **gap junctions**.

#### (ii) Polarity:

- The bottom layer of epithelial cells rests on a **basement membrane** composed of a network of fibers, which include **collagen**, in a matrix of **laminin**.
- The portion of epithelial cells attached to the basement membrane is called the **basal surface**, and the opposite side facing the external environment or the lumen of a body cavity is called the **apical/free surface**. The basement membrane provides structural support to the epithelium, binds the epithelium to neighboring structures, and serves as a scaffolding upon which new cells attach themselves during healing of injured epithelial cells.

#### (iii) Avascularity:

- There are no blood vessels in the epithelial tissue, hence the tissue lacks vasculature. However, nerve endings may occur in the epithelium.

#### (iv) Supported by connective tissue

- Epithelial tissue receives nutrition by diffusion from the underlying connective tissue through the basement membrane.

As the epithelial cells are not supplied with blood vessels, they rely on diffusion of nutrients and oxygen, from lymph vessels, which run through nearby intercellular spaces.

#### (v) Regeneration

- Epithelial cells have a high regeneration capacity, due to rapid cell division. This gives epithelial tissue quick recovery after any injury or abrasions.

#### (vi) Germ cell origin

- Epithelial cells are derived from all the three primary layers; **ectoderm**, **mesoderm**, and **endoderm**. Epithelial cells of the skin, oral cavity, cornea, and lens have **ectodermal origin**. Epithelial linings of blood vessels, pleural and peripheral cavities have **mesodermal origin**. Epithelial linings of the respiratory system and digestive tracts have **endodermal origin**.

### The classification of epithelial tissue

Epithelial tissues are classified according to the **number of cell layers**, and the **shape of the individual cells**.

#### A summary of the classification of epithelial tissue MN 1

13 lines

### 1. Simple epithelial tissue

#### Characteristics of simple epithelial tissue

- Consists of a single layer of cells
- All the cells rest on the basement membrane
- Cuboidal and columnar epithelia may have cilia, and often have **goblet cells** which produce mucus
- Cuboidal and columnar epithelia may possess **microvilli** forming a **brush border**
- The free/apical surface of some epithelial cells may have **stereocilia**.
- Mostly effective for secretion and absorption; but not effective for protection, as simple epithelia are extremely thin.
- Simple epithelia may be **squamous**, **cuboidal**, **columnar**, **ciliated**, or **pseudostratified**.

**Note:**

(a) **Cilia** are hair-like, thin and motile protoplasmic extensions that can move to and fro.

Cilia have a **basal granule** in the cytoplasm, and are associated with the flow of materials in a particular direction, as in the respiratory tract and oviduct

(b) **Stereocilia** are elongated, non-motile, protoplasmic extensions; broad at the base, tapering at the top.

Stereocilia do not have basal granules and are associated with the flow of sperms in the epididymis and vasa deferentia.

(c) **Microvilli** are thin short, closely packed invaginations of the plasma membrane giving a brushborder appearance.

Microvillus increases the surface area for absorption in the nephron and small intestines.

(a) **Cilia**

(b) **Stereocilia**

(c) **Microvilli**

**MN 2**

**6 lines**

**A summary of the characteristics of the types of the simple epithelial tissue**

STRUCTURE	DISTRIBUTION	FUNCTION & ADAPTATIONS
<p>(i) <b>Simple squamous epithelium</b></p> <ul style="list-style-type: none"> <li>• Cells are thin and flattened.</li> <li>• Cells contain little cytoplasm, and the nucleus causes a bulge.</li> <li>• Special junctions bind neighboring cells firmly together</li> <li>• Edges of the cells are irregular (<b>tessellated</b>)</li> </ul>	<ul style="list-style-type: none"> <li>• Renal capsules of kidney</li> <li>• Alveoli of lungs</li> <li>• Lining of blood vessels</li> <li>• Blood capillary walls</li> <li>• Lining of lymphatic vessels</li> </ul>	<p><b>Functions:</b></p> <ul style="list-style-type: none"> <li>• Diffusion of materials</li> <li>• Exchange of gases</li> </ul> <p><b>Adaptations:</b></p> <ul style="list-style-type: none"> <li>• Thin flattened cells to reduce the distances across which materials diffuse</li> <li>• Provides a smooth lining to allow, relatively friction-free passage of fluids and materials through the hollow structures.</li> </ul>
<p>(ii) <b>Simple cuboidal epithelium</b></p> <ul style="list-style-type: none"> <li>• Cube-shaped cells</li> <li>• Cells possess a central, spherical, nucleus.</li> <li>• Cells appear pentagonal or hexagonal in surface view.</li> </ul>	<ul style="list-style-type: none"> <li>• Lining the salivary ducts, pancreatic ducts, convoluted tubules and collecting ducts of the kidneys.</li> <li>• Lining the salivary glands, sweat glands and thyroid glands.</li> </ul>	<p><b>Functions:</b></p> <ul style="list-style-type: none"> <li>• Protection</li> <li>• Excretion</li> <li>• Absorption</li> <li>• Secretion</li> </ul> <p><b>Adaptations:</b></p> <ul style="list-style-type: none"> <li>• Cells are tightly packed together with little intercellular substance between them to offer protection from injury and infection.</li> <li>• Possess many Golgi bodies which perform functions of secretion of hormones and enzymes.</li> <li>• Some possess numerous microvilli which increase surface area, for example for reabsorption of materials from renal fluids in the kidney tubules.</li> </ul>

STRUCTURE	DISTRIBUTION	FUNCTION & ADAPTATIONS
<p><b>(iii) Simple columnar epithelium</b></p> <ul style="list-style-type: none"> <li>• Column-like, tall, narrow cells</li> <li>• Each cell possesses a nucleus at the basal end</li> <li>• Often interspersed with goblet cells</li> <li>• The free surface of each columnar cell may have microvilli forming a brushborder.</li> </ul>	<ul style="list-style-type: none"> <li>• Lining the stomach, small intestines, gall bladder, kidney ducts</li> <li>• Lining gastric glands, intestinal glands, mammary glands, thyroid glands, salivary glands.</li> </ul>	<p><b>Functions:</b></p> <ul style="list-style-type: none"> <li>• Secretion</li> <li>• Protection</li> <li>• Absorption</li> <li>• Brush border increases surface area</li> </ul> <p><b>Adaptations:</b></p> <ul style="list-style-type: none"> <li>• Possess numerous finger-like projections called microvilli which increase the surface area for absorption, such as of digested food in the intestines</li> <li>• Possess mucus-secretory cells; mucus protects the gastric walls from hydrochloric acid and digestive enzymes.</li> <li>• Mucus from goblet cells also lubricates the passage of food in the intestines.</li> </ul>
<p><b>(iv) Ciliated columnar epithelium</b></p> <ul style="list-style-type: none"> <li>• Tall, column-like narrow cells</li> <li>• Cells bear numerous cilia at their free ends</li> <li>• Associated with mucus-secretory goblet cells</li> </ul>	<ul style="list-style-type: none"> <li>• Lines the oviduct, ventricles of the brain, spinal canal and respiratory passages</li> </ul>	<p><b>Functions:</b></p> <ul style="list-style-type: none"> <li>• Mucus protects lining and lubricates the passage of materials.</li> <li>• Cilia set up currents to move materials in a particular direction</li> </ul> <p><b>Adaptations:</b></p> <ul style="list-style-type: none"> <li>• Interspersed with goblet cells which secrete mucus to protect the lining of the gut from enzyme and acid</li> <li>• Possess numerous cilia which beat setting up currents that move materials from one direction to another.</li> <li>• Possess goblet cells which secrete mucus to lubricate the passages</li> </ul>
<p><b>(iv) Pseudostratified epithelia</b></p> <ul style="list-style-type: none"> <li>• One layer of columnar cells that appear to be in two layers</li> <li>• All cells rest on the basement membrane</li> <li>• Not all cells reach the free surface</li> <li>• Nuclei located at different levels</li> <li>• Longer cells have cilia</li> <li>• Shorter cells lack cilia and</li> </ul>	<ul style="list-style-type: none"> <li>• Lining of the urinary tract</li> <li>• Lining of respiratory passages</li> </ul>	<p><b>Functions</b></p> <ul style="list-style-type: none"> <li>• Mucus traps bacteria and dust particles preventing them reaching the lungs</li> <li>• Cilia waft mucus up to the throat for swallowing</li> </ul> <p><b>Adaptations</b></p> <ul style="list-style-type: none"> <li>• Long cells possess cilia which waft mucus with its trapped bacteria and other dust particles up to the throat for swallowing.</li> <li>• The short cells produce mucus which traps bacteria and dust particles in inhaled air</li> </ul>

STRUCTURE	DISTRIBUTION	FUNCTION& ADAPTATIONS
secrete mucus.		

### Illustrations of the different types of simple epithelial tissue:

MN 3 and 4

#### (i) Squamous epithelium:

##### (a) 3-dimensional view

6 lines

##### (b) Vertical section

4 lines

#### (ii) Cuboidal epithelium:

##### (a) Surface view

6 lines

##### (b) 3-dimensionalal view

8 lines

##### (c) Vertical section

4 lines

#### (iii) Simple columnar epithelium:

##### (a) Vertical section

5 lines

##### (b) Brushbordered columnar epithelium

7 lines

#### (iv) Ciliated columnar epithelium

7 lines

#### (v) Pseudostratified epithelium

7 lines

## 2. Compound epithelial tissue

### Characteristics of compound epithelium

- Consists of many layers of cells
- Only the lower layer of cells rests on the basement membrane.
- Mostly used for protection and secretion.
- Compound epithelia may be **stratified** or **transitional**.

#### (i) Stratified epithelium

### Characteristics of stratified epithelium

- Much thicker than simple epithelium, and has many layers of cells.
- Only the lowermost layers of cells rests on the basement membrane.

The basement membrane is **germinal** and gives off more cells by mitotic divisions.

- The first cells to be formed are cuboidal; and as they are pushed outwards they become flattened, cuboid or columnar.
- Being multilayered, stratified epithelium mostly serves a protective function.
- Stratified epithelium maybe **squamous**, **cuboidal** or **columnar**.

**(ii) Transitional epithelium****Characteristics of transitional epithelium**

- Consists of 3 to 4 layers of cells which are all of similar size and shape.
- The cells at the free surface are more flattened.
- The cells are living, large and stretch to change the thickness of the tissue.
- The surface cells do not slough off, and all cells are able to modify their shape when placed under different conditions.

**Distribution:** Transitional epithelium is located where structures are subjected to considerable stretching stress; such as in the urinary bladder, ureter, and the pelvic region of the kidney.

**Adaptations of transitional epithelium for its functions**

- By changing shape, the transitional epithelium allows expansion of the organ, such as the urinary bladder; increasing the volume of the organ.
- Transitional epithelium is composed of many layers of cells making it impermeable to water, thus preventing loss of water from blood to urine.
- Due to its thickness, it prevents urine escaping into the surrounding tissue

**A summary of the characteristics of the types of stratified epithelium**

STRUCTURE	LOCATION	FUNCTION
<b>(i) Stratified squamous epithelium</b> <ul style="list-style-type: none"> <li>• Upper layers of flattened cells called <b>squames</b></li> </ul> <p><b>(a) Keratinized squamous stratified epithelium</b></p> <ul style="list-style-type: none"> <li>• <b>Cornified</b> by heavy deposits of <b>keratin</b> in the upper superficial layers to form a <b>dead horny layer</b></li> <li>• The dead horny layer eventually <b>flakes away</b></li> </ul> <p><b>(b) Non-keratinized squamous stratified epithelium</b></p> <ul style="list-style-type: none"> <li>• Layers of living squamous cells formed by lower cuboidal cells.</li> </ul>	<ul style="list-style-type: none"> <li>• Areas or ducts that are delicate, or have large flow of fluids</li> <li>• External skin surface</li> <li>• Lining of the buccal cavity and vagina</li> <li>• Lining of the pharynx and oesophagus</li> </ul>	<ul style="list-style-type: none"> <li>• Protection and/or secretion</li> <li>• Impervious to water</li> <li>• Protects against abrasion</li> <li>• Resistant to mechanical damage</li> <li>• Protects the underlying tissue from mechanical damage friction as food is swallowed</li> </ul>
<b>(ii) Stratified cuboidal epithelium</b> <ul style="list-style-type: none"> <li>• Layers of cuboidal cells</li> </ul>		

	<ul style="list-style-type: none"> <li>Lining of the large salivary and pancreatic ducts</li> </ul>	<ul style="list-style-type: none"> <li>Protection against mechanical and chemical damage</li> </ul>
<b>(iii) Stratified columnar epithelium</b> <ul style="list-style-type: none"> <li>Layers of columnar cells over many layers of cuboidal cells</li> </ul>	<ul style="list-style-type: none"> <li>Lining the ducts of mammary glands</li> </ul>	<ul style="list-style-type: none"> <li>Protection and secretion</li> </ul>

### Illustrations of the different types of stratified epithelial tissue:

MN 5 and 6

#### (i) Stratified squamous epithelium:

##### (a) Keratinized squamous stratified

##### (b) Non-keratinized squamous stratified epithelium

7 lines

#### (ii) Stratified cuboidal epithelium

7 lines

#### (iii) Stratified columnar epithelium

### Adaptations of epithelial tissue to different functions

**1. Protection:** Epithelial tissue protects the underlying tissues from injury by chemicals, pressure, abrasion and infection.

#### Adaptations of epithelial tissue for protection

- Columnar epithelium lining of the stomach is interspersed with goblet cells which secrete mucus, which protects the stomach lining from the acidic contents of the stomach and from digestion by enzymes, and also lubricates the passage of food thereby protecting the lining from abrasion.
- The shorter cells of the pseudostratified epithelium lining the trachea and bronchi secrete mucus which traps the bacteria and dust particles in inhaled air, and the cilia on the longer cells beat expelling them in the outward direction.
- Keratinized squamous stratified epithelium on external skin surfaces, lining the buccal cavity and the vagina is highly resistant to mechanical damage due to cornification (addition of keratin), protecting the underlying tissue from abrasion.
- The layers of non-keratinized stratified squamous epithelium lining the pharynx and oesophagus are thick, protecting the underlying tissue from mechanical damage by the food that is swallowed.
- The many layers of the cells of the stratified cuboidal epithelium lining the salivary, pancreatic, and sweat ducts, protect them against mechanical and chemical stress.
- The layer of columnar cells of the stratified columnar epithelium lining the ducts of the mammary glands; protects them from mechanical and chemical injury.

**2. Secretion:** A number of epithelial cells are modified to produce secretion such as mucus, enzymes, or hormones.

#### Adaptations of epithelia for secretion

- Cuboidal epithelium lining the salivary glands and thyroid gland secrete saliva, sweat and thyroxine respectively.
- Columnar epithelium lining the stomach is interspersed with goblet cells which secrete mucus.
- The stratified columnar epithelium lining the ducts of the mammary glands secrete fluid

**3. Excretion:** The epithelial cells of the kidney tubules and sweat glands remove excessive and toxic metabolic

wastes the body thus helping the body in excretion.

#### **Adaptations of epithelia for excretion**

- Cuboidal epithelium lining the proximal and distal convoluted tubule and collecting ducts of the kidney are selectively permeable to molecules and ions to facilitate excretion.
- Ciliated cuboidal epithelia lining parts of the nephron have cilia which beat to facilitate the flow of glomerular filtrate.

#### **4. Absorption**

Cuboidal and columnar epithelia are modified for absorption.

#### **Adaptations of epithelia to absorption**

- Squamous epithelium lines the renal corpuscles of the kidney, the alveoli of the lungs and the blood capillary walls, where its extreme thinness permits rapid diffusion of materials through it.
- Cuboidal epithelial cells lining the proximal convoluted tubules possess extensive microvilli forming a brushborder which increases surface area for selective reabsorption of molecules and ions.
- Columnar epithelial cells lining the small intestines possess a brushborder of microvilli which increases the surface area for absorption of nutrients.

#### **5. Exchange of materials and gases**

- Squamous epithelium is extremely thin and flattened promoting exchange of materials and gases by diffusion, such as in the alveoli of the lungs.

#### **6. Sensory**

- Epithelia bearing sensory cells and nerve endings is specialized to receive stimuli, as in the skin and retina of the eye.

#### **7. Movement of materials**

Epithelia may be modified to aid movement of materials

#### **Adaptations of epithelia to move materials**

- Ciliated columnar epithelium lining the inside of the oviducts, ventricles of the brain, spinal canal and the respiratory passages bear numerous cilia at their free surfaces, associated with mucus-secreting goblet cells producing fluids in which the cilia beat rhythmically, setting up currents which move materials from one location to another.
- Pseudostratified epithelium lining the trachea and primary bronchi possess longer ciliated cells and shorter mucus-secreting cells without cilia, and the mucus traps bacteria, dust and other small particles preventing it reaching the lungs, and the cilia wafts mucus up to the throat for swallowing.
- Squamous epithelia lining hollow structures, such as the heart chambers and blood vessels are flat and smooth, allowing friction-free passage of fluids through them.

#### **3. Glandular epithelium**

Glands are secretory in function.

Glands have cuboidal or columnar epithelium called **glandular epithelium**.

#### **The classification of glands**

1. Based on the **kind of secretion** and **duct present**, there are two types of glands; **exocrine** and **endocrine glands**.

EXOCRINE GLANDS	ENDOCRINE GLANDS
-----------------	------------------

<ul style="list-style-type: none"> <li>• Possess ducts</li> <li>• Secretions are mostly enzymes</li> <li>• Secretions pass through ducts to their sites of action</li> <li>• Examples are salivary, tear (lachrymal), gastric and intestinal glands.</li> </ul> <p>These may be <b>unicellular</b> or <b>multicellular</b>.</p>	<ul style="list-style-type: none"> <li>• Do not possess ducts</li> <li>• Secretions are hormones</li> <li>• Secretions reach sites of action through the bloodstream</li> <li>• Examples are pituitary, thyroid, parathyroid, and adrenal glands.</li> </ul>
---	--

**(i) Exocrine glands****(ii) Endocrine glands****MN 7****9 lines**

2. Based on **number of cells**; there are two types of glands, **Unicellular** and **Multicellular glands**

(i) An individual epithelial cell modified into a glandular cell is called a **unicellular gland**, for example the mucus-producing goblet cells.

Cuboidal epithelium interspersed with large numbers of goblet cells constitutes **mucous epithelium**.

(ii) A number of glandular cells aggregate to form a **multicellular gland**.

Multicellular glands may be **simple** or **compound**.

**(i) Unicellular glands****(ii) Multicellular glands****MN 7****7 lines**

3. Based on the **shape and complexity**, the exocrine glands are of two types; **simple** and **compound**.

**(a) Simple glands**

- Simple glands have a **single unbranched duct**
- The secretory part could be in form of a tube called a **tubule** (hence **tubular**) or sacs called **alveoli** (hence **alveolar/saccular**).
- The tubules or sacs may be coiled or uncoiled, branched or unbranched.

**Forms of simple exocrine glands**

<b>(i) Simple tubular glands</b>	<b>(ii) Simple coiled tubular glands</b>	<b>(iii) Simple branched tubular glands</b>	<b>(iv) Simple alveolar/ saccular glands</b>	<b>(v) Simple branched alveolar/saccular glands</b>
<ul style="list-style-type: none"> <li>• Gland is elongated and tube-like</li> </ul> <p><b>Example</b>, the crypts of Lieberkühn in the wall of the mammalian small intestine</p> <p><b>8 lines</b></p>	<ul style="list-style-type: none"> <li>• The secretory tubule of the gland is coiled.</li> </ul> <p><b>Example</b>, the sweat glands in mammalian skin</p> <p><b>8 lines</b></p>	<ul style="list-style-type: none"> <li>• Tubules are branched, but the duct is single</li> </ul> <p><b>Example</b>, Brunner's glands in the wall of the ileum, gastric glands in the wall of the stomach</p> <p><b>8 lines</b></p>	<ul style="list-style-type: none"> <li>• The secretory region is sac-like or flask-shaped</li> </ul> <p><b>Example</b>, mucous glands in the skin of frogs and other amphibians</p> <p><b>8 lines</b></p>	<ul style="list-style-type: none"> <li>• Comprises a number of secretory sacs, opening in the same duct</li> </ul> <p><b>Example</b>, sebaceous /oil glands in the mammalian skin.</p> <p><b>MN 8</b></p> <p><b>8 lines</b></p>

**(b) Compound glands**

- Compound glands have a number of ducts forming a branching pattern.
- The secretory part could be in the form of tubes, called **tubules** or sacs called **alveoli** or both.

#### Forms of compound exocrine glands

(i) Compound tubular glands	(ii) Compound alveolar glands	(iii) Compound tubular-alveolar glands
<ul style="list-style-type: none"> <li>• Secretory part is tubular</li> </ul> <b>Examples</b> , salivary gland	<ul style="list-style-type: none"> <li>• Secretory part is alveolar</li> </ul> <b>Examples</b> , mammary and pancreatic glands	<ul style="list-style-type: none"> <li>• Secretory part comprises both tubules and alveoli</li> </ul> <b>Example</b> , parts of salivary and mammary glands.
<b>8 lines</b>	<b>8 lines</b>	<b>8 lines</b> <b>MN 9</b>

4. Based on the **mode of secretion**, the exocrine glands are of 3 types: **merocrine**, **apocrine** and **holocrine** glands.

#### (a) Merocrine glands

- Secretions released within the cells are discharged on its cell surface without losing any of its cytoplasm.
- The cell therefore remains intact.

**Examples**; goblet cells, pancreatic glands, sweat glands

#### (b) Apocrine glands

Secretions are stored in the apical part of the cell, which bursts open to release its contents.

The cell loses the part of the cytoplasm while releasing its secretion.

**Examples**; mammary glands

#### (c) Holocrine glands

The entire cell breaks down to release its secretions, which extrude from the epithelial surface.

**Example**; sebaceous glands of the mammalian skin

**Note**: Some glands, like mammary glands, have cells secreting in more than one way; they secrete lipids like apocrine glands and proteins like merocrine glands.

5. Based on the **nature of secretion**, glands are of three types; **mucous**, **serous** and **mixed** glands.

#### (a) Mucous glands

Secrete a viscous, mucous fluid

Cells are called **mucous cells** or **mucocytes**

**Example**; goblet cells found in the intestines

#### (b) Serous gland

Secrete a clear, watery fluid containing enzymes

Cells are called **serocytes**

**Examples**; sweat glands

#### (c) Mixed glands

Have both serocytes and mucocytes.

Secrete both serous and mucous secretions.

**Examples**; gastric and pancreatic glands

## (B) CONNECTIVE TISSUE

### The structure of connective tissue

Connective tissue is a composite tissue and has three basic components; **cells**, **fibres** and a **matrix**.

#### (i) Cells

Cells are the living components of connective tissue.

The cells are widely spaced from each other, with large intercellular spaces.

The cells are of various types.

The cells are of mesodermal origin.

#### (ii) Fibres

Connective tissue contains several types of fibre scattered in between cells.

The fibres are the non-living products of the cells.

Fibres form the extracellular material.

**Note:** Blood lacks fibres.

#### (iii) Matrix

The matrix forms the basic ground tissue in which the cells and fibres are suspended.

The matrix is non-living.

The matrix maybe amorphous, transparent, fluid or semi-fluid in nature.

The matrix contains various organic and inorganic substances; the most important being **hyaluronic acid**.

The kind of matrix varies in different tissues

### The distribution of connective tissue

- Present in-between different tissues.
- Present in-between different organs.
- Present in and around body organs.
- Skeletal tissue occurs as bone and cartilage.
- Fluid connective tissue occurs throughout the body.

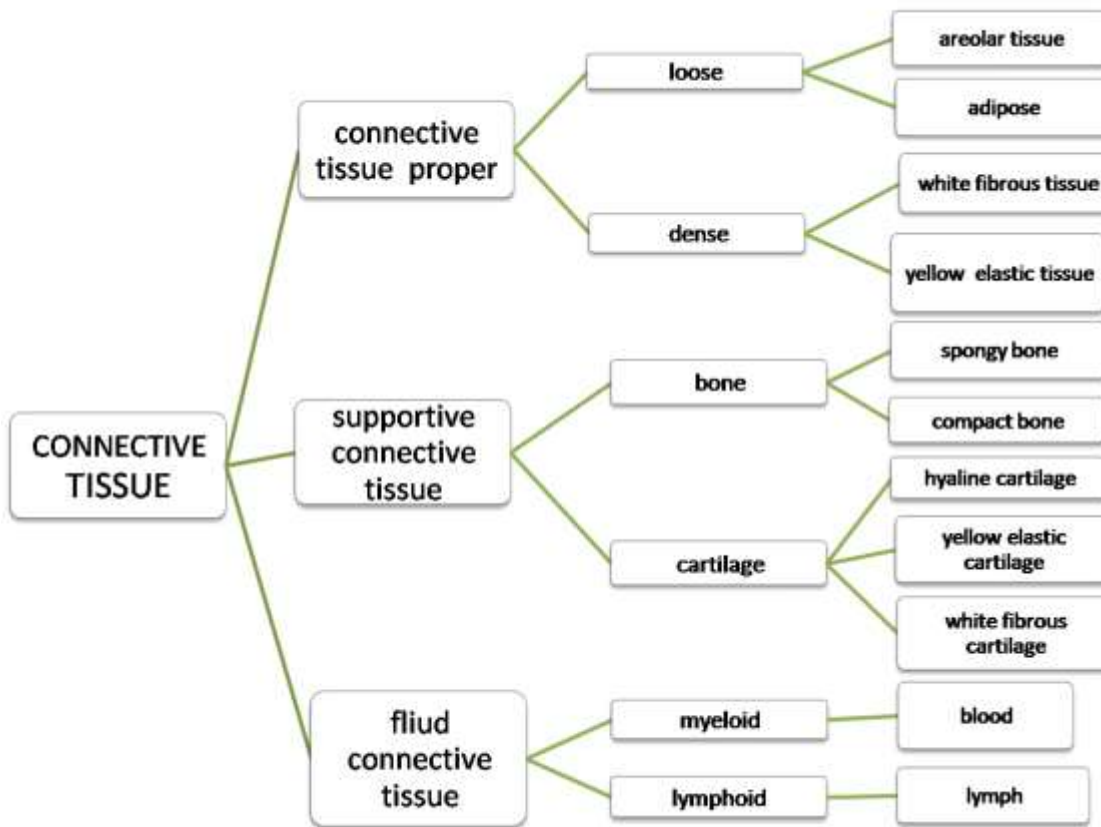
### The functions of connective tissue

- Binds the various tissues together, like skin with muscles and muscles with bone.
- **Packing tissue** forming sheath like bags around the body organs.
- Areolar tissue **protects** the body the body against wounds and infections.
- Adipose tissue **stores fat**, and **insulates** the body against heat loss.
- Connective tissue is the major **supportive tissue** of the body composed of bones and cartilage which provide the body with a supportive framework.
- Haemopoitic tissue **produces blood**.
- Lymphatic tissue builds **body immunity** by producing antibodies.
- Connective tissue separates the body organs, so that they do not interfere with each other's activities.
- Protects blood vessels and organs where they enter or live organs.

### The types of connective tissue

Connective tissue is classified into various types depending on the **kind of matrix** present.

#### Types of connective tissue



**(A) CONNECTIVE TISSUE PROPER**

**LOOSE CONNECTIVE TISSUES**

**1. AREOLAR TISSUE**

The structure of areolar tissue

- Loose connective tissue with widely separated cells.
- Has a different type of fixed and wandering cells.
- Has loosely and randomly woven fibres.
- Consists of a gelatinous glycoprotein **matrix** or **ground substance** containing four main types of cells and two types of protein fibre.
- The **four main types of cells** include; **fibroblasts, mast cells, fat cells, and macrophages.**
- The **two types of fibres** are; **unbranched collagen fibres** and **branched elastic fibres.**
- The ground substance contains a mixture of **glycoprotein, mucin, hyaluronic acid** and **chondroitin sulphate.**

The structure of areolar tissue

FA 36

MN 10

10 lines

The parts of areolar tissue and their functions

PART AND CHARACTERISTICS	ILLUSTRATION	FUNCTIONS/ADAPTATIONS
(a) Type of cell	MN 10, 11	
(i) Fibroblasts		
<ul style="list-style-type: none"> <li>• Spindle-shaped cells.</li> <li>• Flattened cells.</li> <li>• Long protoplasmic processes.</li> <li>• Oval nucleus.</li> </ul>		<ul style="list-style-type: none"> <li>• Produce collagen fibres and elastic fibres.</li> <li>• Can migrate to wounded tissue and secrete more fibres</li> </ul>

PART AND CHARACTERISTICS	ILLUSTRATION	FUNCTIONS/ADAPTATIONS
<ul style="list-style-type: none"> <li>Large and long cells</li> </ul>		to effectively seal the injury.
<p><b>(ii) Macrophages /Histocytes</b></p> <ul style="list-style-type: none"> <li>Large, amoeboid, polymorphic cells.</li> <li>Phagocytic.</li> <li>Kidney-shaped nucleus.</li> </ul>		<ul style="list-style-type: none"> <li>Engulf bacteria and other foreign particles.</li> <li>Ingest damaged cell tissues.</li> <li>Defend body against infections.</li> </ul>
<p><b>(iii) Mast cells</b></p> <ul style="list-style-type: none"> <li>Small, oval-shaped cells.</li> <li>Granular cytoplasm.</li> <li>Found close to blood vessels.</li> </ul>		<ul style="list-style-type: none"> <li>Secrete <b>heparin</b> and <b>histamine</b>.</li> <li>Heparin is an <b>anti-coagulant</b> which neutralizes the action of thrombin, preventing the conversion of prothrombin to thrombin/thrombokinase.</li> <li>Histamine is released from injured tissue, and causes inflammation, vasodilatation, contraction of smooth muscle, and stimulates gastric secretion.</li> </ul>
<p><b>(iv) Plasma cells</b></p> <ul style="list-style-type: none"> <li>Small, round, or irregular cells.</li> <li>Produced by mitotic division of migratory lymphocytes.</li> </ul>		<ul style="list-style-type: none"> <li>Produce antibodies which defend the body against infection and disease</li> </ul>
<p><b>(v) Fat cells</b></p> <ul style="list-style-type: none"> <li>Contain large lipid granules or droplets filling the bulk of the cell.</li> <li>Cytoplasm and organelles confined to the margins.</li> </ul>		<ul style="list-style-type: none"> <li>Stores fat</li> </ul>
<p><b>(vi) Chromatophores</b></p> <ul style="list-style-type: none"> <li>Found in skin and eyes.</li> <li>Highly branched cells.</li> <li>Densely packed with melanin granules.</li> </ul>		<ul style="list-style-type: none"> <li>Produce organ colorations.</li> </ul>
<p><b>(vii) Mesenchyme cells</b></p> <ul style="list-style-type: none"> <li>Undifferentiated cells</li> </ul>		<ul style="list-style-type: none"> <li>Function as undifferentiated cell reserves which can be stimulated to differentiate into any of the above cells.</li> </ul>
<p><b>(b) Type of fibre</b></p>		
<p><b>(i) Collagen/white fibres</b></p> <ul style="list-style-type: none"> <li>Long, wavy, unbranched fibres.</li> <li>Arranged in bundles.</li> <li>Form a loose anastomose network.</li> <li>Flexible, but inelastic as they contain the</li> </ul>		<ul style="list-style-type: none"> <li>Very strong, flexible, and inelastic (do not stretch), thus strengthen the tissue.</li> </ul>

PART AND CHARACTERISTICS	ILLUSTRATION	FUNCTIONS/ADAPTATIONS
protein <b>collagen</b> .		
<b>(ii) Elastic/yellow fibres</b> <ul style="list-style-type: none"> <li>• Long, straight and branched fibres.</li> <li>• Arranged singly to form a fine network.</li> <li>• Flexible and elastic as they contain the protein <b>elastin</b>.</li> </ul>		<ul style="list-style-type: none"> <li>• Network of flexible and elastic (stretchable) fibres; strengthen the tissue, and give tensile strength and resilience.</li> </ul>
<b>(iii) Reticulate fibres</b> <ul style="list-style-type: none"> <li>• Very fine, short, thread-like fibres.</li> <li>• Generally located around blood vessels and nerves.</li> <li>• Quite rigid and composed of immature collagen fibres.</li> <li>• Found covering muscle fibres.</li> </ul>		<ul style="list-style-type: none"> <li>• Strong and inelastic; thus offer tensile strength.</li> </ul>
<b>(c) Ground matrix</b> <ul style="list-style-type: none"> <li>• Mixture of glycoproteins, mucin, hyaluronic acid and chondroitin sulphate.</li> </ul>		<ul style="list-style-type: none"> <li>• Suspends and embeds various fibres and cells.</li> </ul>

#### Distribution of areolar tissue

- Found beneath the skin connecting to the structures below.
- Found all over the body, supporting and connecting tissues together.
- Binds sheets of epithelium to form mesenteries.
- Ensheathes blood vessels and nerves where they enter or leave organs.

#### Functions of areolar tissue

- Binds tissues and organs together.
- Serves as packing tissue filling spaces between adjacent tissues.
- Supports various tissues.
- Provides tissues with resistance against strain and displacement.
- Provides protection against wounding and infection.

#### Allergy

An **allergy** is a condition in which the body produces an abnormal immune response to certain antigens called **allergens**, which include dust, pollen, drugs, fur, and certain foods.

An **allergen** is an antigen that causes an allergic body response.

#### The process of allergic reaction

Allergic reactions occur as a result of an overreaction of the immune system to contact with antigens called allergens.

In a person with an allergy, contact with allergens causes the production of large amounts of a kind of antibody called **IgE**.

These antibodies stimulate **mast cells**, found in all tissues close to the walls of blood vessels, to release excessive amounts of **inflammatory substances**, such as **histamine** and **cytokines**.

These chemicals cause an **acute inflammatory reaction** in which, the blood vessels dilate, which leads to reddening and swelling of the skin and/or exudation of fluids in the tissue; smooth muscle in airways contracts, rashes appear on the skin, tissues swell as fluid accumulates in them.

In some cases, it may lead to bronchial spasms and asthma, or cramps in intestinal muscles.

However, the allergic reaction does not occur on the first contact with the allergen, but only on subsequent contacts when the person is said to have become '**sensitized**'.

## 2. ADIPOSE TISSUE

**Adipose tissue** is a modified form of areolar tissue that contains a large number of fat cells called **adipocytes**.

### The structure of adipose tissue

- Consist of a matrix containing a large number of fat cells called adipocytes arranged into lobules.
- An **adipocyte** is a large spherical cell, almost entirely filled with central fat.
- The fat pushes the cytoplasm, along with the nucleus and organelles to the side of the cell.
- **Adipocytes are of two types; white adipocytes** contain a large central fat droplet; and a **brown adipocytes** contain a number of small fat droplets.

### Distribution of adipose tissue

- Found beneath the skin in the dermis region.
- Found in mesenteries.
- Found around the kidneys, heart and eyeballs.

### The structure of adipose tissue

MN 12

10 lines

### Adaptations of adipose tissue to its functions

- As adipose tissue synthesizes, stores and metabolizes fats; it is a considerable reserve of energy and metabolic water.
- As adipose tissue contains large deposits of fat; it functions as a shock absorber around kidneys, the heart and eyeballs, to prevent mechanical shock
- Since fat is a poor conductor of heat; adipose tissue forms an insulating layer, protecting the body against heat loss.
- Since lipids are less dense than water, large adipose tissue deposits in the blubber of aquatic organisms aid buoyancy and floatation.

## DENSE CONNECTIVE TISSUE

**Dense connective tissue** has more fibres embedded in the matrix than the cells, which makes it more compact than loose areolar tissue.

The fibres maybe regularly or irregularly arranged.

There are two types of dense/compact fibrous connective tissue; **white fibrous tissue (collagen tissue)** and **yellow elastic tissue**.

### 1. WHITE FIBROUS TISSUE

#### The structure of white fibrous/collagen tissue

- Tough, strong, shiny, flexible
- Consists of a glycoprotein matrix, containing densely-packed highly organized bundles of collagen fibres running parallel to each other.
- Rows of fibroblasts are interspersed among the collagen fibres, and run alongside the bundles.
- Fibroblasts produce collagen fibres.
- Each collagen bundle is bound to the other by areolar tissue.

**The distribution of white fibrous tissue**

Abundant in tendons, some ligaments, the sclera and cornea of the eye, the kidney capsule, the perichondrium of cartilage, the periosteum of bones.

**The structure of white fibrous tissue**

MN 13

10 lines

**Adaptations of white fibrous tissue to its functions**

- Composed of numerous, highly organized bundles of collagen fibres, closely packed together, and running parallel to each other; making the tissue strong, tough, flexible, yet inextensible with high tensile strength.
- The collagen fibres are precisely arranged to run parallel to the lines of stress encountered during the functioning of the body structures containing collagen; in order to provide adequate protection against mechanical stress and tension.
- Each strand of collagen possesses three chains of tropocollagen plaited together like a rope; making the tissue extremely strong and tough.

**2. YELLOW ELASTIC TISSUE****The structure of yellow elastic tissue**

- Elastic, flexible and strong fibrous tissue
- Consists of a glycoprotein matrix containing a loose network of irregularly arranged and branched yellow elastic fibres.
- Fibroblasts are randomly scattered throughout the matrix, and some collagen fibres are present.
- Located in ligaments

**Distribution of yellow elastic tissue**

- Found in walls
- Component of lungs, and associated air passages.
- Found in the great cords of the neck.

**Adaptations of yellow elastic tissue to its functions**

- Loose network of irregularly arranged branched yellow elastic fibres give the tissue elasticity and flexibility
- Collagen fibres give the tissue mechanical strength

**(a) Tendons****The structure of tendons**

- Formed by thick bundles of collagen fibres running parallel to each other
- Fibroblasts are arranged in neat rows alongside the collagen fibres
- Collagen fibres arranged parallel to line of stress of structure

**Distribution and function of tendons**

- Tendons join skeletal muscles to bones

**Adaptations of tendons to their function**

- Collagen fibres give tendons strong, flexible but inextensible strength
- Parallel arrangement of collagen fibres running along the lines of stress offers greater resistance to mechanical stress

**(b) Ligaments****The structure of a ligament**

- Loose network of irregularly arranged yellow elastic fibres.
- Some collagen fibres present.
- Fibroblasts scattered in between the yellow elastic fibres and white collagen fibres.

### Functional distribution ligaments

- Ligaments connect bones to bones at the joints, and hold them together.

### Adaptations of ligaments to their function

- Predominant yellow elastic fibres give elasticity.
- Collagen fibres give strength.

### Illustration of tendon and ligament

MN 14

14 lines

### Comparison of tendon and ligaments

#### Similarities between tendons and ligaments

- Both contain a ground matrix of glycoprotein.
- Both contain collagen fibres.
- Both contain fibroblasts.

#### Differences between tendons and ligaments

TENDONS	LIGAMENTS
<ol style="list-style-type: none"> <li>1. Predominantly composed of collagen fibres.</li> <li>2. Fibres regularly arranged in parallel bundles.</li> <li>3. Dense network of fibres.</li> <li>4. Fibroblasts arranged in neat rows alongside fibres.</li> <li>5. Join skeletal muscle to bones.</li> <li>6. Inextensible/inelastic</li> </ol>	<ol style="list-style-type: none"> <li>1. Predominantly composed of yellow elastic fibres.</li> <li>2. Fibres irregularly arranged.</li> <li>3. Loose network of fibres.</li> <li>4. Fibroblasts scattered all over.</li> <li>5. Joins bone to bone at a joint.</li> <li>6. Extensible/elastic</li> </ol>

## SUPPORTIVE CONNECTIVE TISSUES

### SKELETAL TISSUES

#### 1. CARTILAGE

**Cartilage** is a tough, hard, but flexible connective tissue consisting of cells called **chondroblasts** and **chondrocytes**, and **fibres**, suspended in a matrix of **chondrin**.

#### General function

Cartilage is tough, hard and flexible to resist strain and absorb mechanical shock.

#### The structure of cartilage

- The margin of cartilage is enclosed by a dense layer of cells and fibrils called the **perichondrium**.
- Next to the perichondrium is a layer of **chondroblasts**.
- Chondroblasts divide repeatedly into small groups of cells, which gradually get separated from one another; as each secretes a resilient matrix of **chondrin**.
- The matrix possesses many fine **fibrils** mostly made up of **collagen**.
- The chondroblasts eventually become enclosed in spaces called **lacunae**, and become **chondrocytes**.
- Each lacuna contains **two or four** chondrocytes.
- Each chondrocytes is a large, angular cartilage cell with a distinct nucleus.
- There are no processes that extend from the lacunae into the matrix.
- The matrix lacks blood vessels; and exchange of materials between the chondrocytes and matrix is by diffusion only.

- Depending on the nature of the matrix, there are three types of cartilage; hyaline cartilage and white fibrous cartilage.

### Differences between types of cartilage

HYALINE CARTILAGE	ELASTIC CARTILAGE	WHITE FIBROUS CARTILAGE
<p><b>Structure</b></p> <ul style="list-style-type: none"> <li>• The matrix is a glass-like, semi-transparent material consisting of chondroitin sulphate and fine collagen fibrils.</li> <li>• Peripheral chondrocytes are flattened in shape; internal chondrocytes are angular in shape.</li> <li>• Each chondrocytes is contained in a lacuna.</li> <li>• Each lacuna may enclose one, two, four or eight chondrocytes.</li> <li>• No processes that extend from the lacunae into the matrix.</li> <li>• No blood vessels; exchange of materials between the chondrocytes and matrix is by diffusion</li> </ul>	<p><b>Structure</b></p> <ul style="list-style-type: none"> <li>• The matrix is semi-opaque and contains a network of yellow elastic fibres</li> </ul>	<p><b>Structure</b></p> <ul style="list-style-type: none"> <li>• The matrix contains a large number of bundles of densely packed white collagen fibres.</li> </ul>
<p><b>Adaptations</b></p> <ul style="list-style-type: none"> <li>• Slightly elastic and compressible.</li> </ul>	<p><b>Adaptations</b></p> <ul style="list-style-type: none"> <li>• Highly elastic and flexible; thus permits tissue to quickly recover its shape after distortion.</li> </ul>	<p><b>Adaptations</b></p> <ul style="list-style-type: none"> <li>• Provides great tensile strength and a small degree of flexibility.</li> <li>• Functions as a shock-absorber, by providing a cushioning effect.</li> </ul>
<p><b>Distribution</b></p> <ul style="list-style-type: none"> <li>• The elastic, compressible tissue located at the end of bones.</li> <li>• In the nose and air passages of the respiratory system.</li> <li>• In parts of the ear</li> <li>• In the larynx.</li> <li>• It's the only skeletal material of cartilaginous</li> </ul>	<p><b>Distribution</b></p> <ul style="list-style-type: none"> <li>• Located in the external ear, Eustachian tube, and epiglottis.</li> <li>• Forms cartilages of the pharynx.</li> </ul>	<p><b>Distribution</b></p> <ul style="list-style-type: none"> <li>• Occurs as discs between adjacent vertebrae, called intervertebral discs.</li> <li>• Found in the region between the two pubic bones of the pelvis, called the symphysis pubis.</li> <li>• Found in the ligamentous capsules of joints.</li> </ul>

HYALINE CARTILAGE	ELASTIC CARTILAGE	WHITE FIBROUS CARTILAGE
fish/chondrichthyes/elasmobranchs. • Forms the embryonic skeleton in bony vertebrates.		

**Hyaline cartilage**

9 lines

MN 15

**Illustration of lacuna**

5 lines

**Elastic cartilage**

10 lines

**White fibrous cartilage**

9 lines

### Adaptations of cartilage to its functions

- A tough fibrous sheath called the perichondrium surrounds the cartilage; protecting the inner tissue from mechanical damage, infection, and abrasion where bones articulate at the joints.
- Hyaline cartilage comprises a matrix of chondroitin sulphate and fine collagen fibres, making it slightly elastic, compressible, but tough; so it can absorb considerable mechanical shock without breaking, for instance the cartilage joining ribs to the sternum allows limited flexing of ribs during breathing.
- Elastic cartilage comprises a matrix of chondroitin sulphate with a network of yellow elastic fibres, making it highly elastic and flexible, but strong; so it provides mechanical support, and permits tissue to quickly recover its shape after distortion, such as in the pinna of the ear, the epiglottis and pharynx.
- White fibrous cartilage comprises a matrix of chondroitin sulphate, providing great tensile strength, with a small degree of flexibility as it resists stretching; and so provides a cushioning effect and functions as a shock-absorber, such as in the intervertebral discs of the vertebral column of upright bipedal vertebrates.
- In the pubic symphysis between the two bones of the pelvis, the cushioning effect of white fibrous cartilage consisting of many white collagen fibres, gives considerable strength with a degree of flexibility; which allows flexibility at parturition without complete breakage.
- Chondroblasts continuously divide into small group of cells each of which secretes a resilient matrix of chondroitin sulphate.

## 2. BONE

**Bone** is a hard, calcified, connective tissue, made up of cells embedded in a firm matrix.

Bone provides support, protection and metabolites.

About 30% of the matrix is composed of organic substances consisting mainly of collagen fibres; while 70% is inorganic bone salts.

The main component is calcium phosphate, called **hydroxyapatite**,  $\text{Ca}_{10}(\text{PO}_4)_6(\text{OH})_2$ ; but some sodium, magnesium, potassium, chloride, fluoride, hydrogencarbonate, and citrate ions are also present in variable amounts.

The matrix contains the protein **ostein**.

In the matrix, there is a large number of small cavities called **lacunae**, which contain the bone cells called

**osteoblasts**, which secrete the inorganic components of bone.

When osteoblasts are no longer active in matrix secretion, they reduce the number of their cell organelles, and become inactive **osteocytes**, which perform other cellular activities, such as respiration and exchange of materials with the blood.

In the matrix there are small canals called **canaliculi** that contain cytoplasm, and connect the lacunae to each other; and blood vessels passing through the canaliculi provide a means by which osteoblasts exchange materials.

Bone collagen fibres are bound together by a protein called **osteonectin**, and eventually impregnated with apatite crystals.

Bone is surrounded by an outer membrane called the **periosteum**, which contains connective tissue, blood capillaries, nerves, and a number of types of cell; including **osteoclasts**.

### The structure of bone

Each bone is enclosed in a layer of white fibrous connective tissue called the **periosteum**.

**Blood vessels** and **nerves** pierce the bone through the periosteum.

In a bone, the matrix is arranged in concentric circles called **lamellae**.

In between the lamellae is a number of living bone cells called **osteoblasts** or **osteocytes** in the fluid-filled cavities called **lacunae**.

Osteoblasts are active bone cells that secrete the inorganic matrix components; while osteocytes are inactive osteoblasts.

Each lacuna has fine cytoplasmic extensions called **canaliculi** which pass through lamellae and make connections with other lacunae.

### Types of bone

There are **three types of bone**; **compact/dense bone**, **spongy/trabecular bone** and **membrane/dermal bone**.

#### (a) Compact/ dense bone

Compact bone consists of osteoblasts and/or osteocytes in a solid, hard, rigid, organic matrix, with deposits of calcium salts, plus collagen fibres.

#### The structure of compact bone

A **compact bone** consists of numerous cylinders, each surrounding a central **Haversian canal**.

One such cylinder plus its canal is called a **Haversian system** or **osteon**.

#### The structure of the Haversian canal system (osteon)

- Each **Haversian canal system** consists of a **Haversian canal** in the center through which an **artery**, a **vein**, a **lymph vessel** and a **nerve** pass through.
- The matrix is arranged in concentric layers called **lamellae**.
- In between the lamellae are numerous fluid-filled spaces called **lacunae**, containing living bone cells called **osteoblasts** when active or **osteocytes** when inactive.
- Radiating from each lacuna are many fine channels called **canaliculi** containing cytoplasm, which may link up with the central Haversian canal, with other lacunae, or pass from one lamella to another, forming a network of cytoplasmic extensions.
- The bone lamellae and osteoblasts or osteocytes in the lacunae are also arranged concentrically around the Haversian canal.
- The Haversian canal, along with the lamellae, lacunae and canaliculi form the Haversian canal system or osteon.

**A diagram of the transverse section of a Compact bone showing a single Haversian canal system**

**MN 16**

**10 lines**

**The structure of a lacuna containing osteoblasts**

**MN 17**

**7 lines**

- The **canals of Volkmann** connect various Haversian canal systems together.
- Haversian canals are present transversally as well as longitudinally.
- **Transversal Haversian canals** communicate with the bone marrow cavity in the center of the whole bone, and also interconnect with the longitudinal Haversian canals.
- **Longitudinal Haversian canals** contain larger blood vessels, and are not encircled by concentric lamellae.
- In the center of a compact bone lies a **bone marrow cavity** lined by **endosteum**.
- The matrix of a compact bone is composed of collagen, manufactured by osteoblasts, and hydroxyapatite together with quantities of magnesium, sodium, carbonates and nitrates.
- Covering the bone is a layer of dense connective tissue called the **periosteum**.
- Bundles of collagen fibres called **Sharpey-Schafer fibres** from the periosteum pierce the bone.
- The inner region of the periosteum has blood vessels, and forms a layer which contains cells that can develop into osteoblasts.

#### Distribution of compact bone

- Used in growth of long bones of limbs (limb bones).
- Forms the long shaft of the bone between the two swollen ends.

#### (b) Spongy (trabecular) bone

- Spongy bone consists of a meshwork of thin, interconnecting bony struts called **trabeculae**.
- The matrix contains less inorganic materials than compact bone.
- The organic material is primarily composed of collagen fibres.
- The spaces between the trabeculae are filled with soft marrow tissue.
- If the marrow is red, as at the epiphyses of long bones such as the femur, the cells are predominantly red blood cells.
- If the marrow is yellow as in the diaphyses of long bones, the cells are primarily fat cells.
- The matrix of a spongy bone is secreted by osteoblasts, which become inactive osteocytes.
- On the surface and inside the periosteum, are **osteoclasts** which can resorb the calcified bone matrix for further development and restructuring of the bone during growth, development and repair.
- The trabeculae are orientated in the direction in which the bone is stressed.

#### Distribution of spongy bone

- Occurs in the embryo, growing organisms, and epiphyses of long bones

#### Differences between spongy bone and compact bone

SPONGY BONE	COMPACT BONE
1. Consists of small pieces of bone called trabeculae joined together irregularly leaving spaces in between.	1. Matrix is hard, solid and dense without any spaces.
2. Forms the expanded ends (epiphyses) of long bones.	2. Forms the shaft (diaphyses) of long bones.
3. Filled with a soft tissue called red marrow	3. Filled with a fatty tissue called yellow marrow
4. Red marrow produces red blood cells and white blood cells.	4. Yellow marrow stores fat cells.
5. Lacks Haversian canal system	5. Have a number of Haversian canal systems.

#### (c) Membrane (dermal) bone

- Dermal bone is not formed from the embryonic cartilage, but originates directly by **intramembranous ossification** in the dermis of the skin.

- In the dermis of the skin, aggregates of osteoblasts form rows of cells which manufacture bone trabeculae.
- As such, flat bony plates are produced very close to the skin surface.
- The bony plates go on increasing in size, as more bone is deposited on their inner and outer surfaces.
- Eventually the bony plates may sink further into the body to become part of the skeleton.

#### Distribution of dermal bone

- Membrane bone forms components of the skull, jaw bones and pectoral girdle.

#### Differences between cartilage and bone

CARTILAGE	BONE
1. Comparably soft, elastic and flexible.	1. Quite tough, rigid and inelastic.
2. The matrix contains the protein chondrin.	2. The matrix contains the protein casein.
3. Have spherical cells.	3. Have stellate cells.
4. The matrix does not contain deposits of calcium salts.	4. The matrix and the bone cells contain deposits of carbonates and phosphates.
5. The matrix is not arranged in concentric circles.	5. The matrix is arranged in concentric circles called lamellae.
6. Each lacuna has one to eight cartilage cells.	6. Each lacuna has only one bone cell.
7. The lacunae do not have any canaliculi and so cartilage cells are not interconnected.	7. Lacunae have canaliculi and so the bone cells are interconnected.
8. Lacks Haversian canal system.	8. A long bone has a number of Haversian canal systems.
9. The matrix lacks blood vessels.	9. The matrix has a network of blood vessels.
10. Cells occur either singly, or in a group of two or four.	10. Cells arranged singly in a regular pattern.
11. Composed of a solid, elastic matrix.	11. Composed of a hard rigid matrix.
12. Cartilage cells are chondroblasts and chondrocytes.	12. Bone cells are osteoblasts, osteocytes and osteoblasts.

#### Differences between a dried bone and decalcified bone

DRIED BONE	DECALCIFIED BONE
1. Bone subjected it to high temperature.	1. Bone treated with dilute hydrochloric acid.
2. Does not have bone marrow.	2. Has bone marrow.
3. Lacunae present.	3. Lacunae absent.
4. Contains mineral matter.	4. Contains only the organic matter, with no mineral matter.
5. Lacks the structure of a bone, and is in powdered form.	5. Has the structure of a typical bone.

#### Adaptations of bone to its functions

- A tough fibrous layer of dense connective tissue called the periosteum provides a tough and hard covering that surrounds the bone and protects the inner cells.
- Bundles of collagen fibres called Sharpey-Schafer from the Periosteum pierce the bone; giving more mechanical strength; providing an intimate connection between the underlying bone and the periosteum; and functioning as a firm base for insertion of tendons, which contribute to movement and location.
- Osteoblasts are arranged in concentric rings, round a series of Haversian canals in compact bone; thus lay down the matrix in a similar rigid and dense regular pattern, to provide uniform mechanical strength.
- Bone lamellae contain numerous lacunae containing living bone cells called osteoblasts, which secrete the

matrix of the bone.

- Mature less active osteoblasts called osteocytes can be reactivated quickly regaining the structure of active osteoblasts, and depositing bone matrix when structural changes in bone are required.
- Bone cells are embedded in a firm, calcified bone matrix, which is rendered hard by deposits of calcium salts and other inorganic ions.
- Bone matrix comprises collagen, hydroxyapatite together with other mineral ions; the combination of organic and inorganic materials produces a structure of great mechanical strength, which is harder than cartilage but not brittle.
- The matrix and lamellae are laid in a series of cylindrical layers, suited to the forces acting upon the bone, and the load that has to be carried.
- Bone cells called osteoclasts responsible for bone resorption, enable reconstruction and remodeling of bone, during endochondral ossification and repair of damaged and fractured bones.
- An artery, a vein, and a lymph vessel pass through a Haversian canal of compact bone; allowing the passage of nutrients, respiratory gases and metabolic wastes towards and away from the bone cells.
- Each lacuna has fine cytoplasmic extensions called canaliculi which pass through lamellae and make connections with other lacunae and with the central Haversian canal; allowing communication between the lacunae in different lamellae, and with the central Haversian canal.
- Presence of nerve fibres in the Haversian canal allows coordination of bone resorption and reconstruction, enabling each bone to adapt its structure to meet any change in the mechanical requirements of the animal during its development.
- Bone releases calcium and phosphate into the bloodstream, as required by the body, under control of the hormone parathormone and calcitonin.
- Spongy bone has spaces between the trabeculae, reducing the weight of the bone allowing less restricted movement and locomotion.
- The trabeculae of spongy bone are orientated in the direction in which the bone is stressed, enabling the bone to withstand tension and compression forces effectively, whilst at the same time keeping the weight of the bone to a minimum.
- Bone marrow produces red blood cells, white blood cells and platelets.

### 3. DENTINE (IVORY)

Dentine has the same composition as bone.

However, dentine contains a higher inorganic component making it harder than bone.

Dentine contains no lacunae or osteons, and has an arrangement of osteoblasts different from that of bone.

In dentine osteoblasts are confined to the dentinal inner margins and perforate the matrix with many odontoblastic processes which contain **microtubules**, and frequently blood vessels and nerve endings sensitive to touch and low temperatures.

Collagens fibres manufactured and laid down at the apices of the odontoblastic processes ultimately become calcified by impregnation with apatite crystals to form new dentine.

#### Distribution of dentine

Located between the enamel and pulp cavity in teeth, above and below gum level.

#### Functions of dentine

Dentine forms the bulk of teeth

### HAEMOPOIETIC TISSUE

#### Functions of haemopoietic tissue

Forms red blood cells and white blood cells.

### Distribution of haemopoietic tissue

Located in the red bone marrow and lymphoid tissue of adult mammals.

### The structure of haemopoietic tissue

- Haemopoietic tissue consists of free cells enmeshed in a stroma of loose **scleroprotein fibres** called **reticular connective tissue**.
- Bone marrow (myeloid tissue) produces red blood cells and granulocytes.
- Lymphoid tissue produces lymphocytes and monocytes.

### (a) Bone marrow (myeloid tissue)

- The stroma of the myeloid tissue consists of very loose, reticular connective tissue, permeated by wide intercellular spaces.
- Traversed by numerous, thin-walled, wide blood sinuses, through which mature blood cells escape into the bloodstream.
- Lining the sinuses are phagocytic cells which form part of the body's reticulo-endothelial system.

### Functioning of bone marrow

Blood cells are derived from primitive (undifferentiated) cells called:

- **Haemocytoblasts** which differentiate into **erythroblasts**, the precursors of **erythrocytes**.
- **Myelocytes**, the precursors of **granulocytes**.
- **Lymphoblasts**, the precursors of **lymphocytes**.
- **Monoblasts**, the precursors of **monocytes**, and
- **Megakaryocytes**, which produce **platelets**.

### (b) Lymphoid tissue

There are **three types of lymphoid tissue**:

- **Loose lymphoid tissue**, where the stroma of reticular connective tissue predominates over the free cells.
- **Dense lymphoid tissue**, where there are more free cells embedded in the stroma, and
- **Nodular lymphoid tissue**, which possesses dense aggregates of free cells.

The free cells are composed primarily of **lymphocytes** of various sizes and functions.

Also present are **plasma cells** derived from lymphocytes, and occasionally **monocytes** and **eosinophils** are present.

## MUSCLE TISSUE

Muscle tissue is derived from the embryonic mesoderm and consists of highly specialized contractile cells or fibres, held together by connective tissue.

There are **three types of muscle** in the body, classified by the method of innervation; **voluntary muscle**, **involuntary muscle**, and **cardiac muscle**.

### The basic structure of muscular tissue

All muscles are made up of elongated and thin cells called **muscle fibres**.

Muscle fibres contain specialized cytoplasm called **sarcoplasm** that contains a network of membranes called the **sarcoplasmic reticulum**.

Muscle fibres may be bound by a cell membrane called the **sarcolemma**.

Each muscle fibre may contain numerous thin **myofibrils**.

### 1. Voluntary/ striated/ skeletal/striped muscle

#### Distribution of skeletal muscle

Found attached to the skeleton in the head, trunk and limbs (hence the name **skeletal muscle**)

#### The structure of skeletal muscle

Skeletal muscle possesses distinct cross-striations in the form of **light bands** and **dark bands** or **I bands** and **A bands** respectively (hence **striated /striped muscle**).

**I** means **Isotropic**, as it allows light to pass through and so appears lighter.

**A** means **Anisotropic**, as it does not allow light to pass through and so appears darker.

A muscle is composed of a number of cells called **muscle fibres**.

Each muscle fibre consists of numerous thin **myofibrils**.

#### The structure of skeletal muscle fibre

A skeletal muscle fibre is elongated, unbranched and cylindrical in shape.

A number of muscle fibres are arranged parallel to each other and are bound together by vascular connective tissue.

Skeletal muscle fibres are **multinucleate**.

The nuclei are present near the periphery just beneath the bounding membrane called the **sarcolemma**.

**Light** and **dark bands** are visible due to cross-striations present in **myofibrils**.

Myofibrils are arranged along the long axis of the fibre.

#### The structure of a myofibril

Each skeletal myofibril shows alternate **light (I-bands)** and **dark (A-bands)**.

Within the center of an I-band is a dark line called the **Z line**.

Within the center of an A-band is a lighter area called the **H-zone/ H-band/Hensen's disc**.

The area between two Z-lines is called the **sarcomere**.

The **sarcomere** is the basic structural and functional unit of muscle capable of contraction.

A myofibril, and therefore a muscle fibre, is made up of thousands of sarcomeres.

The I and A bands are due to the specific arrangement of two proteins; **actin** and **myosin** present in the form of filaments.

#### The structure of a sarcomere

Various parts of a sarcomere have a specific arrangement of actin and myosin filaments.

Actin forms **thin filaments**, while myosin forms **thick filaments**.

The **I-band** has **only thin actin filaments**.

The **A-band** has **both thin actin and thick myosin filaments**.

The **H-zone** has **only thick myosin filaments**.

The **Z-line** is a membrane to which the actin filaments are attached on both sides.

#### The fine structure of skeletal muscle

BS 635

20 lines

#### Differences between Actin and myosin filaments

ACTIN FILAMENTS	MYOSIN FILAMENTS
1. Made of a thinner and lighter protein called actin.	1. Made of a thicker and heavier protein called myosin.
2. Found in both I and A bands.	2. Found in A-bands only.
3. Cross bridges are absent.	3. Cross bridges are present.

#### Differences between A band and I band

A band	I band
1. Does not allow light to pass through, hence <b>Anisotropic</b> .	1. Allows light to pass through, hence <b>Isotropic</b> .
2. Appears as a darker band under the light	2. Appears as a lighter band under the light

microscope	microscope
3. Has a lighter area called Hensen's disc(H zone)	3. Has a darker line called the Z line at its center
4. Contains both actin and myosin filaments	4. Contains only actin filaments

### Innervation and activity of skeletal muscle

Innervated by the **voluntary nervous system**, that is the **peripheral and central nervous system**. (Hence **voluntary muscle**).

Thus, striated muscle is **voluntary** in function and so works under **one's own will**.

Brings about movement of organs and locomotion of the whole body.

Also brings about the ability of the body part to resist external forces, enabling support of the body and maintenance of body position and posture.

Responsible for voluntary body movements.

Contraction of skeletal muscle attached to the bone allows movement of the body and hence locomotion.

Under goes **powerful and rapid contraction**, with **short refractory (rest) period**; and so gets **easily fatigued**.

Require large amounts of energy in form ATP and so are heavily supplied with numerous blood capillaries, and also have numerous elongated oval mitochondria and numerous glycogen granules.

### Adaptations of voluntary muscle tissue for its function

- Consists of elongated cells called muscle fibres, allowing considerable contractile length.
- Numerous muscle fibres are arranged to each other, giving maximum combined contractile effect.
- The ends of the muscle fibre are tapered and interwoven with each other; to provide adequate mechanical strength during contraction.
- Has a large number of mitochondria to provide a large amount of energy in form of ATP rapidly for rapid contraction.
- Comprises thin actin filaments and thick myosin filaments fitted into each other; to allow sliding over each other during muscle contraction.
- Has a rich supply of blood capillaries to rapidly provide oxygen and nutrients for metabolism, and to rapidly get rid of metabolic wastes.
- Contains respiratory pigment myoglobin, to store oxygen; and release it for respiration when blood oxygen levels are low.
- Has a specialized region called motor end-plate, where the axon of the motor neurone divides and forms fine non-myelinated branches ending in synaptic knobs, running in shallow troughs on the sarcolemma (cell surface membrane) of the muscle fibre, allowing nervous stimulation and nervous control of muscle action.
- The sarcolemma folds inwards and forms a system of tubes called the T-system (transverse tubules), which run through the sarcoplasm to the Z-lines; allowing a nerve impulse arriving along a motor neurone at the neuromuscular junction at the surface of a muscle fibre, to be propagated as a wave of depolarization (action potential) through the T-system, causing release of calcium ions by the sarcoplasmic reticulum to activate the process of muscle contraction.
- The specialized endoplasmic reticulum of the muscle fibre called the sarcoplasmic reticulum forms the vesicles (swollen areas) at the Z-line of the sarcomeres contain calcium ions used to activate the process of muscle contraction.
- Ability to generate ATP using phosphocreatine during anaerobic conditions for a constant supply of ATP in the muscle.
- Ability to respire anaerobically for continued muscle contraction in anaerobic conditions.

## 2. Unstriated/ unstriped/ involuntary/ smooth muscle

### The distribution of involuntary muscle

- Located in walls of intestinal, genital, urinary and respiratory tracts, and walls of blood vessels.
- Found at the base of each body hair, iris of the eye, and in the reproductive system.

### The structure of involuntary muscle

- Smooth muscle consists of densely packed bundles, rings or sheets of elongated muscle fibres, running parallel to each other, and bound by connective tissue.
- Each muscle fibre is spindle-shaped, tapering at both ends, and uninucleate.
- The nucleus is single, elongated in shape, centrally placed, and surrounded by little sarcoplasm.
- The muscle fibre lacks a sarcolemma.
- Each muscle fibre contains numerous, inconspicuous, fine contractile myofibrils arranged longitudinally.
- The actin and myosin filaments are randomly distributed; hence there are no striations or light and dark bands.
- Smooth muscle fibres are shorter than striated muscle fibres.
- Has prominent mitochondria but less numerous than in striated muscles.
- Has individual tubules of the smooth endoplasmic reticulum and glycogen granules.
- Has sarcoplasmic reticulum but less extensive than in striated muscle.
- Rings of smooth muscle fibres are called **sphincter muscles** for example; **pyloric, cardiac and anal sphincters**.

### The fine structure of smooth muscle

MN 18

9 lines

### Innervation and activity of smooth muscle

- Smooth muscle is **involuntary** in action; so **cannot be moved by one's own will**.
- Innervated by two sets of nerves from the **autonomic nervous system** (**parasympathetic and sympathetic nerves**).
- Smooth muscle fibres undergo **prolonged and slow, sustained rhythmical contractions and relaxations** as in peristalsis; hence **fatigue slowly**.
- Functionally smooth muscles are of two types; **single-unit muscles** and **multi-unit muscles**.

### Differences between single-unit muscles and multiunit muscles

SINGLE-UNIT SMOOTH MUSCLE	MULTI-UNIT SMOOTH MUSCLE
1. Muscles fibres closely joined together.	1. Muscle fibres not closely joined together.
2. All fibres, contract together as a single unit, automatically and rhythmically.	2. Individual fibres contract as separate units more or less as independent muscle.
3. Present in the walls of hallow visceral organs, as in the stomach, intestine, urinary bladder.	3. Present in hair roots, and walls of large blood vessels.

**Note:** Humans learn to control many smooth muscles, for example humans control the movement of the anal sphincter muscles.

### Functions of involuntary muscle

- The pyloric sphincter controls passage of food from the stomach to the duodenum.
- The anal sphincter controls the elimination of feces from the body.
- Small sphincter muscles surround some blood vessels, controlling distribution of blood and regulating blood pressure.
- Control movement of materials within the body visceral organs.

### 3. Cardiac muscle

#### Distribution of cardiac muscle

Found only in the heart.

### The structure of cardiac muscle

A cardiac muscle consists of a network of interconnected cells called **cardiac muscle fibres(myocytes)**.

- Each cardiac muscle fibre is short, cylindrical, and branched.
- Each cardiac muscle fibre possesses one or two centrally-placed nuclei, numerous large mitochondria, abundant cytoplasm, glycogen granules, a well-developed T-system, and poorly developed smooth endoplasmic reticulum consisting of a network of tubules.
- Cardiac muscle fibres are terminally branched and connected to each other by special interdigitating processes (zigzag junctions) called **intercalated discs**.
- Actin and myosin filaments are regularly arranged to give faint, but regular cross-striations.
- Muscle fibres branch and cross-connect with each other to form a complex net-like arrangement.

### Illustration of the structure of cardiac muscle

BS 471

7 lines

### Innervations and functions of cardiac muscle

Cardiac muscle is **myogenic** meaning their contractions are developed within the muscle.

The rate of contraction can be influenced by the **autonomic nervous system**.

Interconnections between the fibres ensure a rapid and uniform spread of the excitation.

Have **rhythmic rapid contractions and relaxations with a long refractory period**, and so **do not fatigue**, as **contraction is not sustained**.

Need a constant supply of large amounts of energy.

A small number of cardiac muscle fibres and a few nerve endings from the autonomic nervous system form a **sinoatrial node**, located near the opening of the vena cavae, which stimulates heart beat on their own.

### Adaptations of cardiac muscle to its function

- Cardiac muscle cells are highly branched terminally, and connected to each other by special interdigitating processes called **intercalated discs** to form a network; that allows rapid spread of waves of electrical excitation from cell to cell, so that linked cells rapidly contract rhythmically and simultaneously, for fast heartbeat.
- Dense network of numerous blood capillaries ensures adequate supply of oxygen and food nutrients, for fast production of adequate Adenosine triphosphate/ATP, for continuous rapid muscle contraction; and rapid excretion of carbon dioxide and other metabolic wastes.
- Numerous large mitochondria and numerous glycogen granules rapidly provide adequate amounts of energy in form of Adenosine triphosphate/ ATP by aerobic respiration, for continuous rapid contraction without fatigue.
- Has Sino-atrial node/SAN which emits waves of electrical excitation that initiate continuous and rhythmic contraction without fatigue, for continuous heartbeat.
- Has striations that provide mechanical strength to support its fast and continuous contractions.
- Undergoes rapid rhythmic contractions and relaxations with long refractory period, and thus does not fatigue as contraction is not sustained.
- Well-developed T-system for rapid transmission of impulses; thus rapid contraction and relaxation
- Branched muscle fibres offer a large surface area for fast spread of waves of electrical excitation, for continuous contraction, hence continuous heartbeat.

### A comparison of voluntary, involuntary and cardiac muscle; similarities and differences

FEATURE	STRIATED MUSCLE	SMOOTH MUSCLE	CARDIAC MUSCLE
---------	-----------------	---------------	----------------

FEATURE	STRIATED MUSCLE	SMOOTH MUSCLE	CARDIAC MUSCLE
<b>Names</b>	Striated, striped, voluntary, striated muscle	Unstriated, unstriped, smooth, involuntary, non-striated muscle	Heart muscle, cardiac muscle
<b>Specialization</b>	Mostly highly specialized	Least specialized	More specialized than involuntary
<b>Shape</b>	Elongated, cylindrical, and unbranched muscle fibres	Spindle-shaped muscle fibres, with tapered ends	Elongated, cylindrical, and branched muscle fibres
<b>Arrangement</b>	Arranged in bundles	Arranged in bundles, sheets, or rings	Interconnected forming a network
<b>Sarcolemma</b>	Present	Absent	Present
<b>Nucleus</b>	Multinucleate myofibrils with peripherally located nucleus	Uninucleate myofibrils with centrally-located, elongated nucleus	One or two nuclei in-between intercalated discs.
<b>Cytoplasmic contents</b>	Numerous mitochondria in rows at periphery and between fibres Prominent SER forming network of tubules T-system well-developed Glycogen granules and some lipid droplets	Prominent, but less mitochondria  Individual tubules of SER  Glycogen granules present	Numerous large mitochondria  Poorly developed SER consisting of network of tubules T-system well developed Glycogen granules present
<b>Blood supply</b>	Rich blood supply	Poor blood supply	Rich blood supply
<b>Striations or bands</b>	Striations of light and dark bands present	No striations or bands	Faint, regular striations present
<b>Intercalated discs</b>	Absent	Absent	Present
<b>Myofilaments/ myofibrils</b>	Very conspicuous	Inconspicuous	Conspicuous
<b>Innervation</b>	Under control of voluntary nervous system	Under control of autonomous nervous system	Myogenic; but rate of contraction can be influenced by autonomous nervous system

FEATURE	STRIATED MUSCLE	SMOOTH MUSCLE	CARDIAC MUSCLE
<b>Contractions</b>	Powerful, rapid contractions, with short refractory (rest) period	Shows sustained slow and rhythmic contractions and relaxation; with long rest period	Continuous, rapid, rhythmical, contraction and relaxation; with long refractory period; hence contraction not sustained
<b>Fatigue</b>	Fatigues quickly and easily	Does not get fatigued easily	Does not fatigue
<b>Location</b>	Attached to the skeleton in the head, trunk and limbs	In walls of intestinal, genital, urinary and respiratory tracts in walls of blood vessels	Only in the walls of the heart
<b>Energy</b>	Large amount of energy at one time	Much less energy, but constant supply required	Needs a constant and good energy supply
<b>Mode of working</b>	Voluntary	Involuntary	involuntary

## NERVOUS TISSUE

**Nervous tissue** contains densely packed nerve cells called **neurons**, which are specialized for conduction of nerve impulses, and form the nervous system.

Among other cells present are **receptor cells** and **Schwann cells**.

Nervous tissue is frequently enclosed by connective tissue which contains blood vessels.

Neurons have two basic functional properties; **excitability** and **conductivity**.

### Neurons

**Neurons** are the basic structural and functional units of the nervous system.

### Function of neurons

Neurons transmit electrical impulses, thus providing a means of communication between **receptors** (the cells or organs which receive stimuli) and **effectors** (the organs or tissues which respond to stimuli, such as muscle and glands).

### Types of neurons

- (i) **Sensory neurons** conduct impulses towards the central nervous system (brain and spinal cord).
- (ii) **Motor neurons** conduct impulses away from the central nervous system.
- (iii) **Interneurons** frequently connect sensory neurons with motor neurons.

### The structure of different types of neurons

(a) **Sensory/ afferent neurons**

**BS 193**

**10 lines**

(b) **Motor/efferent /effector neurons**

**BS 193**

**10 lines**

(c) **Interneurone / intermediate /association/ internuncial /relay neurons** **BS 193**

**10 lines**

### The structure of a neuron

Each neuron possesses a **cell body (soma or perikaryon)** and **cytoplasmic extensions (nerve fibres)**.

Each cell body or soma contains a nucleus and abundant granular cytoplasm.

The cytoplasm contains numerous cell organelles, such as mitochondria, Golgi apparatus, RER and neurofibrils. The cytoplasm also contains prominent conical, angular or rhomboidal granules called **Nissl's granules**, which are groups of ribosomes and rough endoplasmic reticulum, rich in RNA and associated with protein synthesis. From the cell body, extends out two types of cytoplasmic extensions; **dendrons** and **axons**. Depending upon the number and arrangement of these processes, the neurones are said to be **unipolar**, **pseudounipolar**, **bipolar**, or **multipolar**.

- (a) A **unipolar neurone**, such as the arthropod motor neurone MN 19  
7 lines
- (b) A **pseudounipolar neurone** MN 19  
6 lines
- (c) A **bipolar neurone**, such as from the mammalian retina MN 19  
10 lines
- (d) A **multipolar neurone**, such as the mammalian spinal cord MN 19  
12 lines

- A **unipolar neurone** is one which the axon is the only large branch from the cell body.
- A **bipolar neurone** is one with one axon and one dendron.
- A **multipolar neurone** has one axon and several dendrons.

Nerve fibres which conduct impulses away from the cell body are called **dendrons**. Dendrons are small, relatively wide, and break up into fine terminal branches called **dendrites**.

Nerve fibres which conduct impulses away from the cell body are called **axons**.

Axons are thinner than dendrites and maybe several meters long.

The end of an axon breaks up into fine branches with swollen endings called **synaptic knobs**.

Synaptic knobs are neurosecretory and release **neurotransmitters**, such as **acetylcholine**.

Axons communicate with other neurones via gaps called **synapses**.

Each axon is filled with cytoplasm called **axoplasm** that is continuous with the cytoplasm of the cell body.

The axoplasm contains numerous mitochondria, RER, neurofibrils, but lacks Nissl's granules, Golgi apparatus and a nucleus.

The axon is covered by a membrane called the **axolemma**.

#### Differences between the dendron and axon

DENDRON	AXON
1. Shorter, numerous, branched.	1. Longer, fewer, generally unbranched.
2. Have fine terminal branches.	2. Have terminal end branches with swollen ends (synaptic knobs)
3. Conduct nerve impulses towards the cell body.	3. Conduct nerve impulses away from the cell body.
4. Have Nissl's granules and Golgi apparatus	4. Do not have Nissl's granules and Golgi apparatus.

#### Types of nerve fibres

There are two types of nerve fibres; **myelinated** and **non-myelinated nerve fibres**.

##### (a) Myelinated/medullated nerve fibres

**Myelinated nerve fibres** are completely surrounded and insulated by a fatty **myelin sheath**, formed by another

type of cell called a **Schwann cell**.

The cytoplasm remains in a region called the **neurilemma** around the myelin sheath.

The myelin sheath is interrupted at regular intervals by constrictions called **nodes of Ranvier**.

The nodes occur between the Schwann cells, and one Schwann cell nucleus is visible in the sheath between each successive pair of nodes.

The cell surface membrane of the Schwann cell becomes extended and wraps itself like a roll of carpet round and round the nerve fibre.

This extension forms the myelin sheath, which is mainly lipid and lacks the protein normally found in membranes.

The neurilemma is strictly speaking the membrane of the Schwann cell.

At nodes of Ranvier the axon is surrounded by the axolemma and neurilemma only.

### A longitudinal section through an axon

P&C 171

10 lines

### An illustration of the development of a myelin sheath

P&C 171

10 lines

### (b) Non-myelinated/ non-medullated nerve fibre

**Non-myelinated nerve fibres** are those without a myelin sheath.

These lack nodes of Ranvier, and are only surrounded by Schwann cells which do not form a myelin sheath.

**Note:** Diseases such as Multiple sclerosis and Tay-Sachs disease cause destruction of myelin sheaths.

### Differences between myelinated and non-myelinated nerve fibres

MYELINATED NERVE FIBRES	NON-MYELINATED NERVE FIBRES
1. Nerve fibres have a myelin sheath surrounding the axon.	1. No myelin sheath surrounding the axon
2. Have nodes of Ranvier at regular intervals.	2. Nodes of Ranvier absent
3. Nerve fibres are thicker.	3. Nerve fibres are thinner.
4. Nerve impulses travel at a much faster speed.	4. Nerve impulses travel at much slower speeds.
5. Present in cranial and spinal nerves, in the central nervous system and peripheral nervous system.	5. Present in autonomic nervous system.

### Adaptations of neurones to their functions

- The cell body contains a prominent nucleus and most of the nerve cell's other organelles, to control the metabolic functioning of the cell.
- A group of ribosomes and rough endoplasm called Nissl's granules produce proteins required for transmission of a nerve impulse.
- The cytoplasm of the cell body, dendron and axon contain numerous mitochondria to produce large amounts of energy in form of ATP for active processes involved in impulse transmission, such as the sodium-potassium pump.
- Schwann cells of myelinated axons form a fatty myelin sheath with high electrical resistance, which insulates the axon of the neurone, leading to increased speed of impulse transmission, through salutatory conduction.
- The myelin sheath of myelinated axons is interrupted at regular intervals by breaks called nodes of Ranvier,

where the resistance to current flow between the axoplasm and the fluid outside the cell is lower, and at these points local circuits are setup and current flows across the axon membrane to generate the next action potential, leading to increased speed of impulse transmission.

- Nerve fibres contain neurofibrils for transportation of materials from the cell body to the nerve fibres and from the nerve fibres to the cell body.
- Dendrites make synaptic connections with the neighboring excitatory cells and tissues allowing transmission of nerve impulses from cell to cell.
- Giant axons typical of annelids, arthropods and mollusks, have a large diameter of approximately 1mm, which decreases the resistance of the axoplasm to ionic exchange, increases the length of axon membrane influenced by local circuits, lengthening the distance between adjacent depolarizations, leading to increased velocity of impulse transmission.
- Neurones are long cells, whose length depends on their precise role in the nervous system, for example, motor neurones supplying the muscles in the giraffe's leg are several meters long, allowing conduction of impulses to and from all parts of the body.
- Special gaps between the nerve cells called synapses, allow nerve impulses to be transmitted from one neurone to another, either by chemical or electrical transmission.
- Size and shape of neurones varies widely to meet the nervous needs of the body, from unipolar, pseudounipolar, bipolar to multipolar; depending on the extent of the nervous links required.
- Sometimes, the axon divides into branches called **collaterals**, so that impulses from one neurone can reach several different destinations, increasing dexterity and complexity of nervous coordination of the body.
- Integration of synaptic input received by dendrites is focused on a specialized region of the cell body called the **axon hillock**, until a threshold level is reached, and the axon Hillock fires a nerve impulse into the axon.

## NERVES

**Nerves** consist of bundles of nerve fibres in a connective tissue sheath called the **epineurium**.

Each nerve fibre is surrounded by a sheath of connective tissue called the **endoneurium**.

A number of nerve fibres are bound together in smaller bundles by a connective tissue called the **perinerium**.

**The transverse section of a nerve fibre**

**MN 20**

**8 lines**

### Types of nerves

Nerves are classified according to the direction in which they convey impulses.

- Sensory/afferent nerves** convey impulses to the CNS, for example the olfactory, optic, and auditory nerves.
- Motor/efferent nerves** conduct impulses away from the CNS, for example the oculomotor, pathetic, abducens.
- Mixed nerves** convey impulses in both directions, for example the spinal nerves, trigeminal, facial, vagus, glossopharyngeal.

## MISCELLANEOUS

## Neuroglia cells

In the CNS connective tissue is almost absent, and the majority of the interneuron space is filled by special non-nervous cells called Neuroglia cells (Glial cells)

### Functions of Neuroglia cells

Bind the nervous tissue together by functioning as packing cells filling the spaces in-between.

Function as packing cells providing mechanical and metabolic support to the delicate network of neurones carrying the nerve impulses.

Involved in the memory process by storing information, in form of an RNA code.

Provides nourishment to the cytoplasmic extensions (nerve fibres) of the neurones.

Satellite Neuroglia called Schwann cells synthesise the myelin sheath of myelinated nerve fibres.

Ependyma cells line the brain cavities and spinal canal, and form an epithelial layer in the choroid plexus these serve to connect the cavities with the underlying tissues.

Microglia is divided into categories; astrocytes and oligodendrocytes.

Protoplasmic astrocytes are located in the grey matter. These possess numerous branches, short thick processes radiating from the cell body; which contain an ovoid nucleus and much glycogen.

Fibrous astrocytes are located in the white matter. These possess fewer branches, long processes radiating from the cell body, which contain an ovoid nucleus and much glycogen.

The branches of astrocytes but upon the walls of the blood vessels; and the astrocytes convey nutrients from the blood stream into the neurone.

Both types of astrocytes are interconnected forming an extensive three dimensional network in which neurones are embedded; and also divide frequently to form scar tissue if the central nervous system is injured.

Oligodendrocytes are located in the grey and white matter. These are smaller than astrocytes and possess a spherical single nucleus; and fewer, finer branches radiate from the cell body which contains cytoplasm rich in ribosome.

Note; Schwann cells are specialized oligodendrocytes

Microglia are located in the grey and white matter but are more numerous in the grey matter.

Microglia possess thick processes arising from the end of a small elongated cell body which contain lysosomes and a well developed Golgi apparatus. All branches possess further lateral branches.

When the brain is damaged microglia are stimulated to become Phagocytic and more round in amoeboid fashion to combat invasion of foreign particles.

Microglia is capable of dividing and regenerating and thus repairs the injured tissues.

**Note;** due to their ability to divide, microglia is the major sources of brain tumors.

### Differences between neurons and neuroglia

Neurones	Neuroglia
Conduct nerve impulses from one part of the body to another. Incapable of division. Specialized to carry information only to and from the CNS Much less in number	Do not conduct nerve impulses; but bind nerve tissues together. Capable of division and regeneration. Specialized forms can perform nutritive, Phagocytic and regeneration function. Ten times more numerous than neurons.

## Multiple sclerosis

Multiple sclerosis is a major neurological disease that results in the gradual deterioration (demyelinated) of the myelin sheath around the neurones of the brain and spinal cord in demyelinated regions hardened scars or plaques called scleroses replace the sheath.

### **Effects of multiple sclerosis**

The scleroses interfere with transmission of nerve impulses, slowing them down and causing a gradual loss of motor activity.

### **Symptoms of multiple sclerosis (Ms)**

Loss of coordination

Blurred vision

Body weakness

### **Cause of Ms**

Proteins within the myelin sheath are attacked by enzymes from the body's immune system.

### **Occurrence of multiple sclerosis**

More common in temperate regions than in tropical regions.

Affects more men than women.

May progress unrelentingly or have intermittent periods of relapse and remission.

### **Treatment of multiple sclerosis**

No cure of multiple sclerosis.

Symptoms relieved by therapy

Rate of relapse reduced by steroids and other drugs

## **BLOOD TISSUE FLUID AND LYMPH**

### **The development of bone [ossification]**

Ossification is the process of formation and development of bone.

Bone originates in two ways; intramembranous ossification and endochondral ossification.

#### **Intramembranous ossification**

The thin bony plates of the skull and parts of some other bones are formed directly by cluster of ossification which appears inside fibrous membranes.

The strands of bone formed by different clusters are called trabeculae, and become linked to form a loose network described as spongy bone.

Thus spongy bone is formed by intramembranous ossification.

As development continues, remodeling of skull plates converts some of the spongy bone to compact bone and allows the plates to reach their adult shape and size.

#### **Endochondral ossification**

Endochondral ossification is the process of replacement of cartilage by bone.

The skeleton of a vertebral embryo consists mainly of hyaline cartilage

Each cartilage element is surrounded by a connective tissue jacket; the perichondrium is the same shape as the bone that replaces it. Thus the cartilage acts as a model for bone formation.

Ossification of bones (such as the long bones of the arms and legs) begins when blood vessels penetrate the perichondrium of the cartilage mid-way along the shaft (or diaphyses) of the cartilage model. Vascularisation stimulates some of the cells of the cartilage perichondrium to become osteoblasts, which produce a collar of compact bone in the shaft region. The jacket of connective tissue covering the developing bone is now called the Periosteum.

A primary ossification centre appears inside the shaft, and is progressively invaded by a proliferating number of blood vessels and osteoblasts. The matrix of the cartilage tends to become calcified by deposition of calcium and phosphate, but is eroded by the osteoclasts, leaving spaces, leaving spaces which eventually fuse to form the marrow cavity.

Osteoclasts are large multinucleated bone cells, similar to macrophages, which continually erode the bone matrix. Like other macrophages. Osteoclasts develop from monocytes. Working in small groups, osteoclasts tunnel through bone, leaving cavities which are invaded by blood capillaries and new bone-forming osteoblasts.

Within the tunnel, osteoblasts lay down a new bone matrix in concentric rings, forming an arrangement called a Haversian canal system.

**An illustration of the formation of bone by osteoblasts**

**An illustration of the remodeling of bone by osteoclasts**

Cartilage continues to grow at either end producing an increase in length. Most of cartilage is later replaced by spongy bone.

In mammals, secondary ossification centers develop in the swollen ends (or epiphyses) of the cartilage models of long bones. The epiphyses ossify more or completely, except for a thin layer of cartilage, called an epiphyses plate, separating each epiphysis from the main shaft and a thin surface layer of articular cartilage. This arrangement gives the bone, strong rounded ends but permits continued increase in length.

Increase in diameter of the bone shaft is achieved by continual remodeling and deposition of new bone by the osteoblasts of the Periosteum.

As maturity approaches, the thickness of the epiphyseal plates is reduced and finally, the epiphyses and the bone shaft fuse completely leaving a faint epiphyseal line.

Ossification of all bones in human skeleton is normally completely by age 25.

**An illustration of the process of endochondral ossification**

**Cartilage model**

**Collar formation**

**Proliferation of blood vessels**

**Secondary ossification centers**

**Adult bone**